

# A Self-study Program for the Family Physician Interested in No-scalpel Vasectomy

---



American Academy  
of Family Physicians

No-scalpel  
Vasectomy

# Table of Contents

[Disclaimer](#)

[CME Credit Information](#)

[Contributors](#)

[Contributor Disclosure](#)

[About the Author](#)

[Learning Objectives](#)

[Introduction](#)

Chapters

- |                               |  |
|-------------------------------|--|
| <a href="#"><u>One</u></a>    | <a href="#"><u>A Less Invasive Vasectomy</u></a>                   |
| <a href="#"><u>Two</u></a>    | <a href="#"><u>Surgical Setup, Instruments and Preparation</u></a> |
| <a href="#"><u>Three</u></a>  | <a href="#"><u>NSV Video Demonstration</u></a>                     |
| <a href="#"><u>Four</u></a>   | <a href="#"><u>Vasal Block Anesthetic</u></a>                      |
| <a href="#"><u>Five</u></a>   | <a href="#"><u>NSV Step-by-Step</u></a>                            |
| <a href="#"><u>Six</u></a>    | <a href="#"><u>Care After No-scalpel Vasectomy</u></a>             |
| <a href="#"><u>Seven</u></a>  | <a href="#"><u>Patient Concerns</u></a>                            |
| <a href="#"><u>Eight</u></a>  | <a href="#"><u>Vas Occlusion Options</u></a>                       |
| <a href="#"><u>Nine</u></a>   | <a href="#"><u>Management of Complications</u></a>                 |
| <a href="#"><u>Ten</u></a>    | <a href="#"><u>Clinical Outcomes of Vasectomy</u></a>              |
| <a href="#"><u>Eleven</u></a> | <a href="#"><u>Adding Vasectomy to Your Practice</u></a>           |

[Resources](#)

[Test](#)

[References](#)

# Disclaimer

Additional information and training can be obtained by attending a course on No-scalpel Vasectomy, through other written material, and most importantly, by performing these procedures under the direction of an experienced preceptor.

This material is not intended to represent the only methods or procedures appropriate for the medical situations discussed, but rather is intended to present an approach or opinion of the author that may be helpful to other physicians who are presented with similar situations. Every effort has been made to ensure the accuracy of the data included in the manual and videotape. Physicians should check specific details, such as drug doses and contraindications, in standard sources prior to clinical application.

---

# CME Credit Information

This activity has been reviewed and is acceptable for up to 5 Prescribed credit hours by the American Academy of Family Physicians.

The AAFP is accredited by the Accreditation Council for Continuing Medical Education (ACCME) to provide continuing medical education credit for physicians.

The AAFP designates this educational activity for a maximum of 5 hours in category 1 credit toward the American Medical Association Physician's Recognition Award. Each physician should claim only those hours of credit that he/she actually spent in the activity.

The AAFP has determined this course to be a level 2 classification in accordance with the AMA guidelines for Continuing Medical Education on New Procedures and Skills.

## AAFP Members

AAFP Members wishing to obtain CME credit should complete and return the enclosed posttest to the CME Productions Department, American Academy of Family Physicians, 11400 Tomahawk Creek Parkway, Leawood, Kansas 66211-2672. (These hours will automatically be added to your continuing medical education records.)

## Nonmembers

Physicians who are nonmembers should complete the posttest and return it to the CME Productions Department, American Academy of Family Physicians, 11400 Tomahawk Creek Parkway, Leawood, Kansas 66211-2672. A letter documenting course completion will be sent automatically upon receipt of the posttest.

---

# Contributors

## Author

Charles L. Wilson, M.D., Clinical Associate Professor of Family Medicine, University of Washington School of Medicine, Seattle, Washington and Private Practice, Seattle, Washington.

## Medical Reviewer

Camille Collett, M.D., Auxillary Faculty, Associate Professor, Department of Family and Preventive Medicine, University of Utah Medical College, Family Physician, Salt Lake Community Health Centers, Salt Lake City, Utah.

## Editors

Sarah Smiley, Projects Editor, Publications Division and Susanna E. Guzman, Special Projects Manager, AAFP Publications Division

## AAFP Project Manager

Sandy Shelton, Manager, CME Program Services, Division of Continuing Medical Education

## AAFP Project Coordinator

Chandra Orthel, Senior CME Program Coordinator, Division of Continuing Medical Education

## Illustrator

Larry Howell, Graphic Artist

## Production of Videotape

Rick Waggener, Editor, Blue Springs, Missouri  
Charles L. Wilson, M.D., Seattle, Washington

## Videotape Animation

William Honan, Kansas City, Missouri

---

# Contributor Disclosure

The AAFP has selected and provides funding for all contributors appearing in this program. According to the AAFP policy, all relationships between the author and propriety entities that may have a direct interest in the subject matter of their presentations will be disclosed.

The following contributors have returned disclosure forms indicating they have no affiliation or financial interest in any organization(s):

Charles L. Wilson, M.D.  
Camille Collett, M.D.  
Larry Howell  
Rick Waggener  
William Honan

Dr. Wilson is the designer of the Wilson Vasectomy Forceps; however, he has no financial arrangement/interest with any organization(s) that may have a direct interest in the subject matter.

The above contributors have also declared that the content of their materials will not include discussion of unapproved uses of a product or products.

---

## About the Author

Charles L. Wilson, M.D., is a family physician in private practice in Seattle, Washington and a Clinical Associate Professor of Family Medicine at the University of Washington School of Medicine. Since 1978, he has pursued a special interest in vasectomy, including designing innovative vasectomy instruments and recently introducing the no-needle anesthetic technique for vasectomy. He has performed over 4,500 no-scalpel vasectomy procedures.

Dr. Wilson teaches vasectomy skills to family physicians and residents. Since 1992, he has contributed to clinical procedures workshops for the AAFP and others.

---

# Learning Objectives

Upon completion of this program, the participant should be able to:

1. List the benefits and risks of vasectomy as a contraceptive method, as well as the potential advantages, possible complications and their management, of the no-scalpel vasectomy (NSV) technique.
  2. Describe the special instruments used and key steps involved in NSV as compared with the traditional technique.
  3. Describe the process for patient selection and counseling, including the screening examination.
  4. Describe and demonstrate three-finger fixation of the vas.
  5. Plan the office setup and preparation of staff for performing vasectomies.
-



# Introduction

Vasectomy is a valuable procedure ideally suited to the family practice office setting. No-scalpel vasectomy is a refined method of vasectomy, is more accepted by patients and has become increasingly popular.

This learning package will present information about the role of vasectomy and specific details of the no-scalpel technique so that family physicians and others with general surgical experience may become more skilled in their application. Before applying these methods in practice, we strongly recommend that the learner obtain hands-on guidance in an actual surgical setting, accompanied by a preceptor who is skilled in no-scalpel vasectomy technique. The education, certain aspects of which can only be gained in this manner, is well worth the effort and cost.

Optimizing provider skills through advanced training and practice will ensure the best outcomes of vasectomy and thereby foster wider acceptance of this valuable procedure in the community.

## Vasectomy in the United States

Sterilization is the most popular method of contraception for married couples in the United States. In about two-thirds of couples who have chosen sterilization, the woman has undergone tubal sterilization; in the other one-third, the man has undergone vasectomy (Figure 1). About 500,000 vasectomies are performed in the United States each year. The prevalence is about 10 per 1,000 men aged 25 to 49 years.<sup>1</sup> Considering the advantages of vasectomy over tubal sterilization (Table 1), one may conclude that vasectomy is chosen by less than half of those who are good candidates for the procedure. This apparent underutilization can be attributed to several factors: lack of awareness, lack of funding, lack of access, complacency, uncertainty and fears.

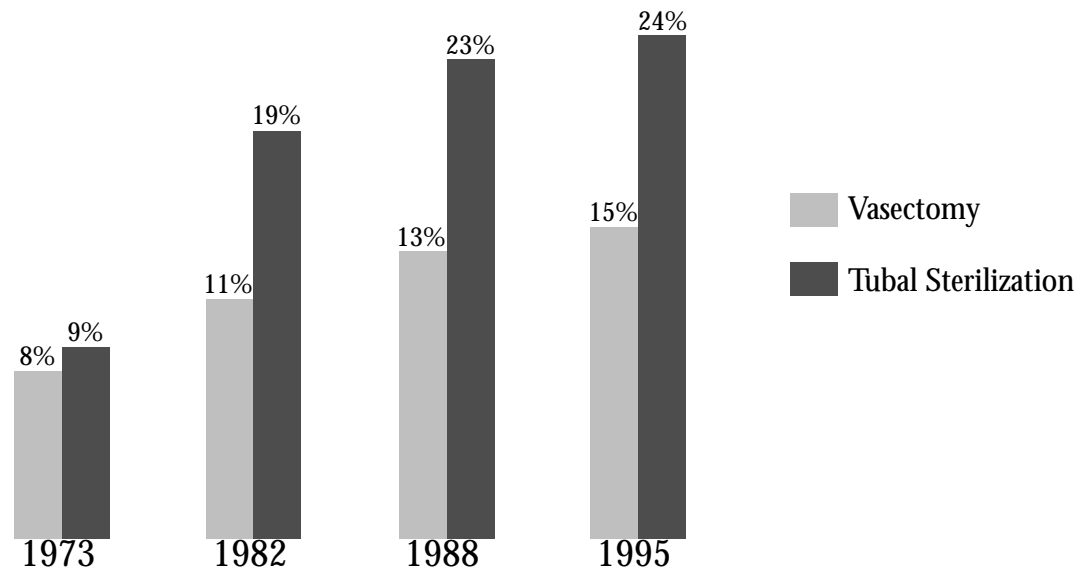
More public education about vasectomy is needed, and family doctors are ideally suited to disseminate knowledge about vasectomy, and to increase the procedure's accessibility.

---

Figure 1

## Prevalence — Vasectomy vs. Tubal Sterilization

Married women age 15-44 using contraception



Tubal sterilization outpaces vasectomy by 1.6:1

*CDC Center for Health Statistics National Survey of Family Growth, June 1998*

Table 1

### Tubal sterilization vs. vasectomy

- Tubal sterilization poses excess anesthesia risk associated with use of general anesthesia.
- Tubal sterilization offers no better efficacy with no test of success.
- Failure of tubal sterilization can result in dangerous ectopic pregnancy and emergency surgery.
- Vasectomy can be performed in a nonhospital setting, so even rural practices without a hospital can offer it.
- Vasectomy can be performed at lower cost.

# A Less Invasive Vasectomy

## No-scalpel Vasectomy History

In the Sichuan Province of China in 1974, the ratio of tubal sterilization to vasectomy was 2:1, about the same as it was in the United States.<sup>2</sup> Dr. Li Shunqiang, director of the Chongqing Family Planning Scientific Research Institute, introduced the technique for no-scalpel vasectomy. He hoped to increase the acceptance of vasectomy by eliminating fear of incision and to reduce morbidity by limiting the extent of dissection. Other physicians, including Schmidt and Denniston in the United States, had demonstrated the benefits of smaller incisions, but it was Dr. Li's innovative use of the *sharp dissecting forceps* that made it possible to access the vas through a simple puncture wound. Dr. Li's success spread throughout China, and by 1990, 8 million Chinese men had undergone no-scalpel vasectomy.<sup>3</sup> In Sichuan Province, the ratio of tubal sterilization to vasectomy had been reversed to 1:5.<sup>2</sup>

In 1985, Western physicians visiting China observed the technique, and in 1986 Dr. Marc Goldstein from Cornell Medical School returned to China to learn the technique directly from Dr. Li. In 1988, the Association for Voluntary Surgical Contraception (AVSC) sponsored a workshop to introduce the new procedure in the United States. By 1995, a survey showed that 3,700 physicians had performed almost one-third of all vasectomies using no-scalpel technique.<sup>4</sup>

## What is No-scalpel Vasectomy (NSV)? (Table 2)

The NSV procedure is a strictly defined sequence of precise steps that lead to an extremely efficient delivery of the vas with the very least trauma (Table 3). The procedure concludes with presentation of the bare vas for occlusion, but does not dictate the method of occlusion.

NSV introduced a new and effective method of anesthesia for the vas: the perivasal block. The three-finger fixation of the vas overcomes one of the common difficulties encountered in getting started in vasectomy. Using the *vas-fixing forceps* to steady the vas through the skin makes it possible to securely grasp the vas, which is essential before the skin can be punctured.

---

Table 2

### What is no-scalpel vasectomy?

- A refined method of accessing the vas
- Same end result as traditional vasectomy
- No difference in the method of occluding the vas
- A minimally invasive procedure

Table 3

### Key steps of no-scalpel vasectomy

- Three-finger fixation
- Perivasal block
- Grasping with the vas-fixing forceps
- Puncture and delivery of the vas
- Dissecting a loop of vas

The puncture, when performed with careful alignment, separates all layers of surrounding fascia to expose the vas. The dense population of blood vessels in the fascia is safely separated by this atraumatic technique, typically resulting in no bleeding at all.

The hook and delivery movement is unique. It takes courage to release the secure grasp of the vas-fixing forceps and to trust that the vas will slide from its sheath, allowing it to be grasped again without dropping out of sight. Finally, the sharp dissecting forceps are used to delicately strip the fascia from the bare loop of vas, presenting an avascular segment for occlusion.

### Advantages and Disadvantages of NSV

The NSV has several advantages over traditional incisional vasectomy (Table 4). Effectiveness of the perivasal anesthetic and less traumatic handling of the tissues may reduce discomfort both during and after the procedure. There is little or no bleeding and, therefore, less risk of

---

postoperative hematoma or infection. Efficient delivery and dissection of the vas makes the procedure a fairly quick one, and excellent exposure of the vas makes occlusion easy and definitive. Because of minimal tissue trauma, recovery is generally uneventful.

Potential barriers to NSV (Table 5) include the necessity of special instruments and unique surgical skills. Clearly, advantages multiply as experience grows. Most physicians will be comfortable with NSV after performing 10 to 15 procedures, and will likely be unwilling to return to incisional technique after performing about 30 NSV procedures.

Table 4

#### **Advantages of no-scalpel vasectomy**

- **Less discomfort**
- **Less risk of bleeding and infection**
- **Quick office procedure**
- **Reduced recovery time**

Table 5

#### **Disadvantages of no-scalpel vasectomy**

- **Requires special instruments**
  - **Requires special training**
  - **Time commitment necessary to gain benefits**
-

## Chapter 2

# Surgical Setup, Instruments and Preparation

## Surgical Setup

Like other minor office surgeries, vasectomy can be performed in a procedure room or exam room that has adequate space for the patient and his partner, and allows for the physician and any staff to move easily. The room should be clean and well lighted, and all supplies and equipment needed should be on hand. An assistant should be standing by to handle any needs the surgeon, the patient or the patient's partner might have.

---

**TIP** — Some doctors warm the room to encourage relaxation of the scrotum, but it is important that the temperature be comfortable for the surgeon as well. If necessary, a warm water bottle may be placed over the scrotum for 15 minutes prior to the procedure. If the scrotum is short and tight in a comfortably warm room, adding more heat to the room will produce more tension in the surgeon than relaxation in the patient.

---

A standard exam table is fine for this procedure if it is at a comfortable height for the surgeon. A power table with optional Trendelenburg position may prove helpful for the occasional patient who becomes light-headed or syncopal due to vasovagal reaction.

Good lighting is essential. A high-intensity halogen surgical lamp is ideal. A common gooseneck lamp with standard bulb is less than desirable.

Figure 2 shows a typical sterile surgical tray setup for no-scalpel vasectomy. Table 6 lists the suggested instruments and supplies.

Either 4-0 chromic gut suture or another absorbable suture material may be used for fascial interposition. Some surgeons prefer to use metallic clips on the fascia. Clips can help avoid fascial tissue bleeding from the use of the suture needle, but a sterile applicator instrument must be kept on hand. Also, the suture may be more useful for hemostasis.

---

Figure 2 — Typical sterile tray setup for NSV.

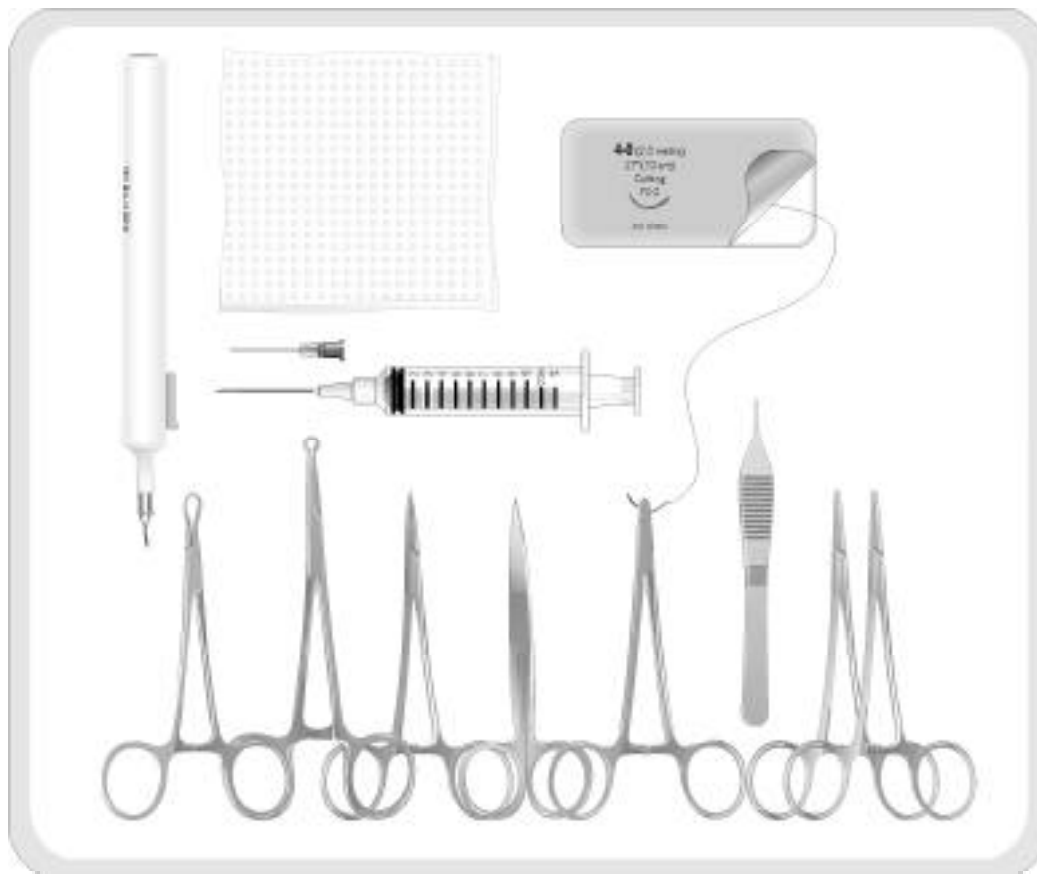

Table 6

### Suggested instruments and supplies for NSV tray

- 2 mosquito hemostats
- 1 or 2 vas-fixing forceps
- 1 sharp dissecting forceps
- 1 Adson forceps with teeth and suture platform
- 1 sharp suture scissors
- 1 needle holder with 4-0 chromic gut or other suture
- Electrocautery unit with sterile needle tip or sterile battery-powered cautery unit with long tip
- 6 4x4-inch gauze pads
- 10cc syringe with a 25- or 27-gauge 1.5-inch needle

### Additional supplies on hand

- Nonsterile exam gloves
- Tape or rubber band to retract penis
- Razor or scissors to trim scrotal hair
- Antiseptic surgical prep solution
- Sterile gloves
- Fenestrated sterile drape or surgical towels
- 1% or 2% lidocaine without epinephrine, or 0.25% or 0.5% bupivacaine without epinephrine
- A topical anesthetic, such as 2.5% lidocaine, 2.5% prilocaine combination cream (Emla cream), placed over the operative site 30 minutes before the procedure (**optional**).

## NSV Instruments

Two special instruments are used in NSV. The first is the vas-fixing forceps, a locking clamp that closes to form a ring around the vas. The blunt tips approximate with enough force to keep the vas from slipping out of the ring but without traumatizing the skin and perivascular tissues. After delivery of the vas, this clamp regrips the exposed loop of vas between its blunt tips. There are two styles of vas-fixing forceps. The Chinese style, designed by Dr. Li specifically for the NSV, has a smaller ring (available in three diameters: 3.0, 3.5 or 4.0mm) that restricts the grasping volume, and has a cantilever design that limits the grasping pressure at the closed tips (Figure 3). The U.S. style, originally designed by Dr. Wilson as an aid to incisional vasectomy, has a shorter distance from hinge to tip and therefore grasps more tightly (Figure 4). The ring volume of the Wilson clamp also allows for grasping thicker scrotal tissues around the vas. It may be beneficial to have one of each style of vas-fixing forceps on the NSV tray.

The second instrument is the sharp dissecting forceps (Figure 5). This curved clamp is similar to a mosquito hemostat, with sharpened tips that meet precisely. It is used to puncture the skin and fascia, to spread the tissue layers, to delicately push aside blood vessels, and to hook and

Figure 3 — Chinese vas-fixing forceps (Li).

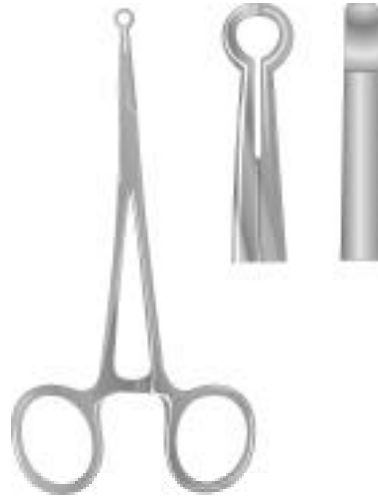

Figure 4 — U.S. vas-fixing forceps (Wilson).

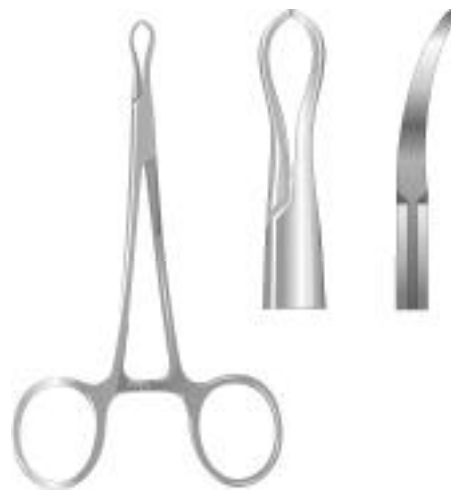
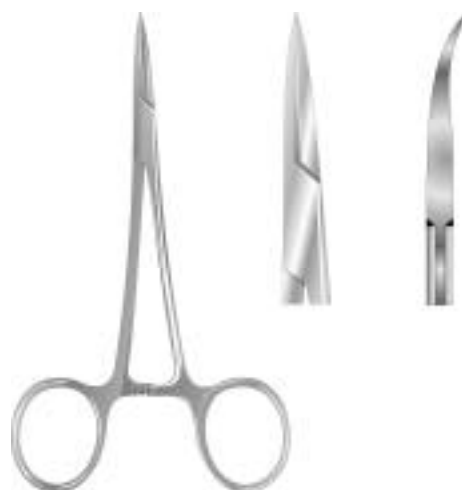
Figure 5 — Sharp dissecting forceps.





deliver the vas from its sheath. This clamp may be used to grasp tissues, but because of the sharpness of the tips, a hemostat may work better. Care must be used in handling the sharp dissecting forceps, both to protect the tips from damage and to protect from injury the staff who handle and clean this sharp instrument.

## Anatomy and Examination

Figure 6 demonstrates the desirable site for vasectomy. The point of incision is located in the midline at the junction of the superior one-third and the inferior two-thirds of the scrotum. At this level, the vasa are most likely to be straight, firm and easily mobilized to the proper position.

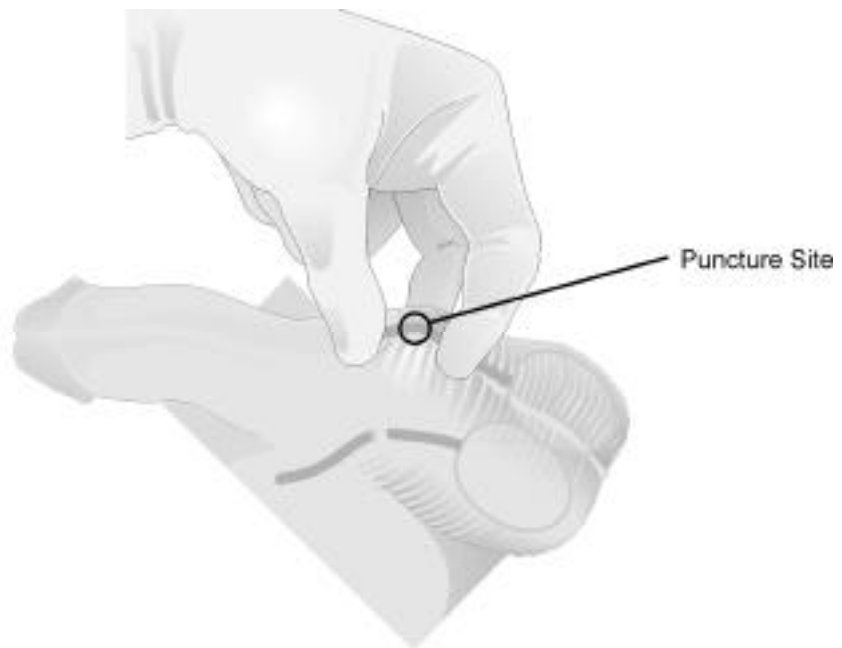
Perform an examination at the beginning of the procedure, even if a prior exam was done. Observe for skin infections, masses, and congenital or acquired structural anomalies.

Document your findings. Be alert to the rare possibility of a duplicate vas on one or both sides

or to the absence of one vas. It is a good idea to also alert the patient to any significant findings, as he may first discover an anatomic feature after his vasectomy — when there is heightened awareness of the area — and incorrectly conclude that it was caused by the vasectomy.

Be absolutely certain at this point that you can identify by palpation and mobilize each vas to the proposed midline puncture site. A slippery prep solution (e.g., chlorhexidine [Hibiclens, BactoShield, Betasept]) can facilitate palpation. If there is any question about a successful outcome, it is

Figure 6 — Desirable site for vasectomy: In the anterior midline at the junction of the superior one-third and inferior two-thirds of the scrotum



best to stop before any invasive step is taken and get a consultation. Avoid the mistake of thinking it will somehow become easier to isolate the vas during the procedure than it was during the exam.

### Positioning the Patient

The patient reclines comfortably on the table, lowering his pants and underwear to the knees. He is already wearing clean, brief-style underwear and keeps his shoes and pants on so it is easy for him to dress after the procedure.

Retract the penis cephalad. The penis can be held in this position by a rubber band looped around the corona and clipped to the patient's shirt by a towel clip, but I prefer to use a 6-inch piece of tape from the penis to the abdominal wall, avoiding the glans.

### Surgical Prep

If the anterior scrotum is obscured by hair, it may be trimmed with scissors or shaved with a prep razor, but limit the shaving to the minimum needed for an unobstructed operative site. A length of tape is handy for collecting loose hairs after trimming or shaving and before applying prep solution. Warm the prep solution before application to prevent reflex dartos contraction. Be sure to prep both the anterior and posterior scrotum and adjacent skin, since your fingers will be placed behind the scrotum during the procedure. Do not prep beyond the base of the penis. Finally, drape the operative site using folded towels or a fenestrated sterile drape.

### Gentle Reassurance

Start very slowly and gently. The typical patient is nervous and is primed to overreact to any movement or touch that is not smooth, gentle and reassuring. Once you have gained the patient's confidence by establishing gentle contact, it is easier to proceed at a normal pace. Give the patient accurate cues as to what he will feel at each step. Offer verbal relaxation by conversing about pleasant or interesting topics (e.g., vacations, sports, hobbies). Background music in the room may also promote relaxation, though headphones can interfere with important verbal communication.

---

## Chapter 3

# NSV Video Demonstration

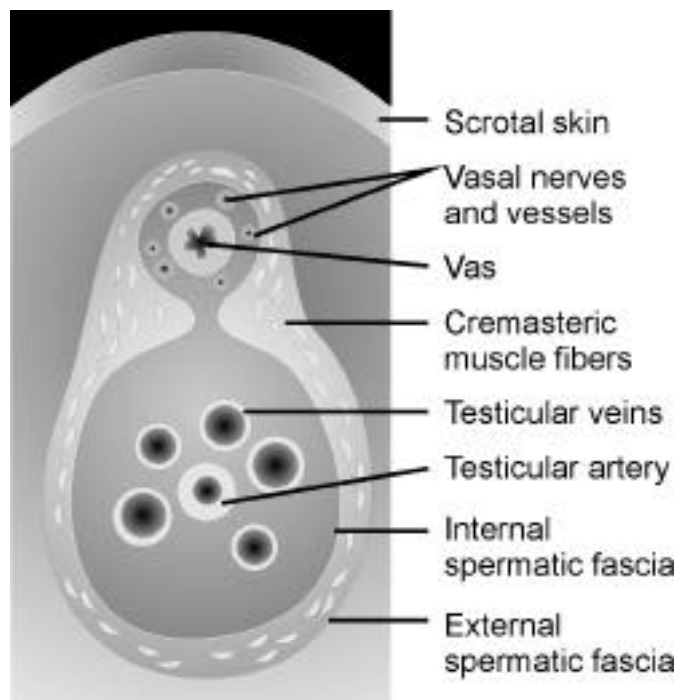
View the procedure in this 14-minute video, narrated by Dr. Wilson, in which he demonstrates both typical procedures and potential pitfalls.

# Vasal Block Anesthetic

The vasal block, an anesthetic technique introduced with the NSV, is more effective than local infiltration because it blocks the small vasal nerves at a point 2 to 3 cm superior to the operative site, and because it does not contribute to local swelling. These small nerves course along the surface of the vas, within the internal spermatic fascia (Figure 7). The objective is to make a paravasal injection by advancing the needle cephalad parallel to and immediately beside the vas. Thus, the inferior segment of the vas is anesthetic to pressure, cutting and cautery, yet there is no swelling of tissues at the operative site.

The recommended method is to administer the vasal block anesthetic on both vasa prior to proceeding with the vasectomy. It might seem impractical to move from one vas to the other, but once practiced in the method of three-finger fixation of the vas, it is not a problem to release each vas and regrasp it. This sequence also allows more time for the anesthetic to take effect on each side.

Figure 7 — Cross section of the spermatic cord.



---

**TIP** — In cases where it seems particularly difficult to locate the vas, you could change the sequence by simply completing the vasectomy on the first side, then proceeding to anesthetize the second side, ensuring that on each side adequate time passes for anesthetic effectiveness.

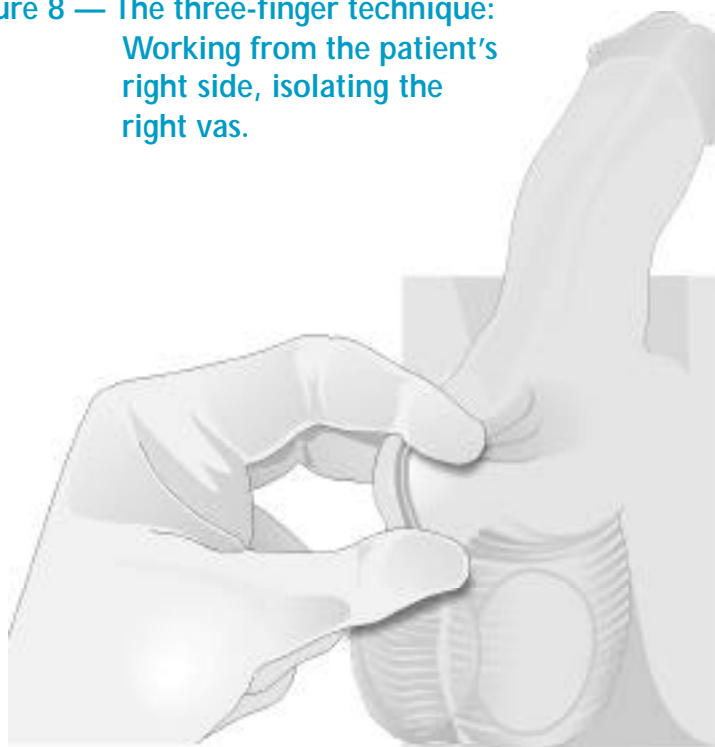
---

You stand to the patient's right side for the entire NSV procedure if you are right-handed, and to his left side if you are left-handed. You should begin working on the same side with every patient, usually the vas closest to you (Figure 8). Your body position changes from facing toward the patient's head when working on the closer side, to facing more toward the patient's feet when reaching across to the opposite side (Figure 9). The instructions that follow are based on using the right hand as the dominant hand, and standing on the right side of the patient.

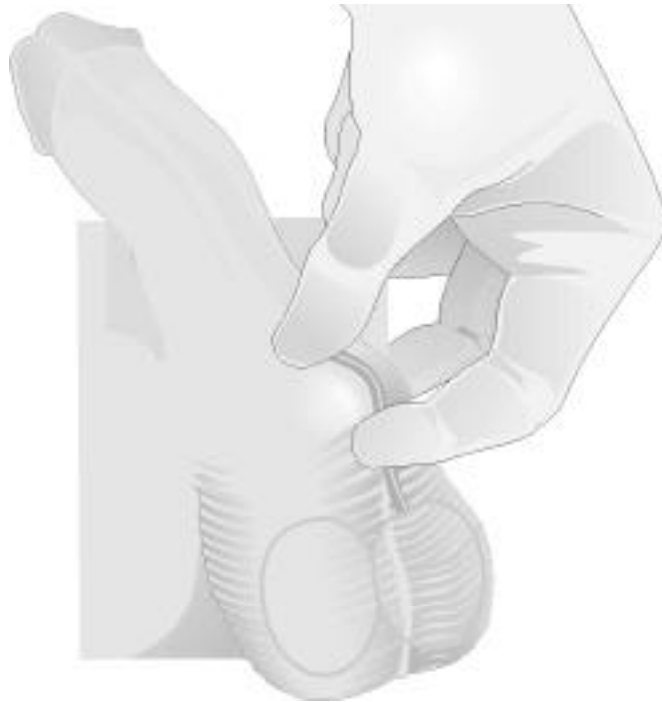### Three-Finger Fixation of the Vas

You will use the three-finger fixation to secure the vas both during the administration of the vasal block anesthetic, and later when you grasp the vas in the vas-fixing forceps. Begin with your nondominant hand, extending your middle finger and placing it transversely behind (posterior to) the scrotum, with your thumb on the anterior scrotum. Palpate the vas between your thumb and middle finger. Place your index finger over the anterior scrotum about 2 cm superior to your thumb, creating a window between them and securing the vas as it courses over the pad of your middle finger (Figure 8). Adjust your grasp until the window includes the junction of the superior one-third and the inferior two-thirds of the scrotum. Manipulate the vas to lie under the median raphe.

Figure 8 — The three-finger technique:  
Working from the patient's  
right side, isolating the  
right vas.



**Figure 9 — The three-finger technique: Working from the patient's right side, isolating the left vas.**



---

**TIP** — Sometimes isolating the vas is difficult and you may feel that an alternative approach is needed. Or, you may not know which vas is being palpated. You may want to start at the inferior scrotum with your middle finger posterior and thumb anterior, compressing the midline and separating the two testicles. Slide your grasp cephalad in the midline to the level of the upper one-third of the scrotum. Now you have isolated the vasa onto their respective sides. Then, rolling finger against thumb, work your grasp laterally. You will encounter the vas, which feels dense and noncompressible. It usually lies in the posteromedial aspect of the spermatic cord. Do not allow the vas to slip medially through your grasp; keep it lateral. Pinch firmly to hold the vas from slipping. If it slips laterally, it is easy to regain fixation, but if it slips medially, you will need to re-isolate it.

---

## Injection

The usual anesthetic agent is 1 percent or 2 percent lidocaine without epinephrine. A 10 cc syringe is adequate; a 25-gauge, 1-inch or 1 1/2-inch needle is of small caliber, yet is stiff enough to advance predictably in the intended direction.

---

**TIP** — Some patients are quite apprehensive about the needle injection. Some physicians offer a topical anesthetic, such as 2.5 percent lidocaine, 2.5 percent prilocaine combination cream (Emla cream), which can be placed over the injection site with an occlusive dressing 30 minutes before the procedure and will eliminate the sharp sensation of needle entry, though not the deeper sensations.

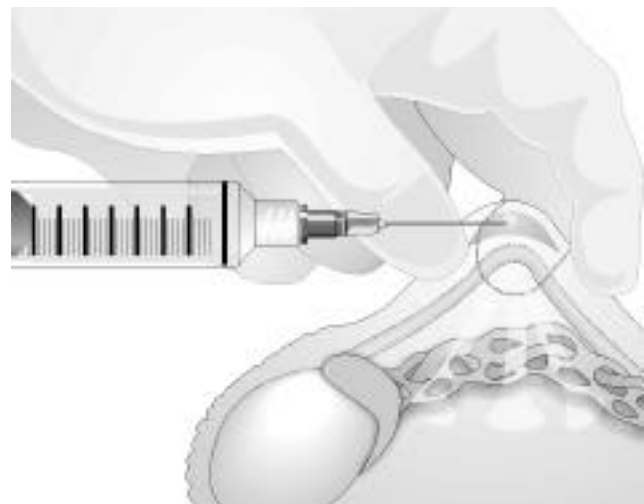
---

Now, with the vas securely fixed in the three-finger grasp, raise a 1-cm wheal in the skin at the intended site, one-third of the way down the scrotum, in the median raphe (Figures 10, 11). Advance the needle 2 to 3 cm in the direction of the inguinal canal, along the vas and within the perivasal sheath, without penetrating the vas. Ensure that the vas courses directly toward the inguinal canal by applying traction on the vas. Once the needle is in place, inject 2 to 4 cc of anesthetic solution (Figure 12). It is not necessary to inject at several different points, since the anesthetic will diffuse around the vas within the perivasal sheath, which contains the vasal nerves.

Figure 10 — Raising the skin wheal.

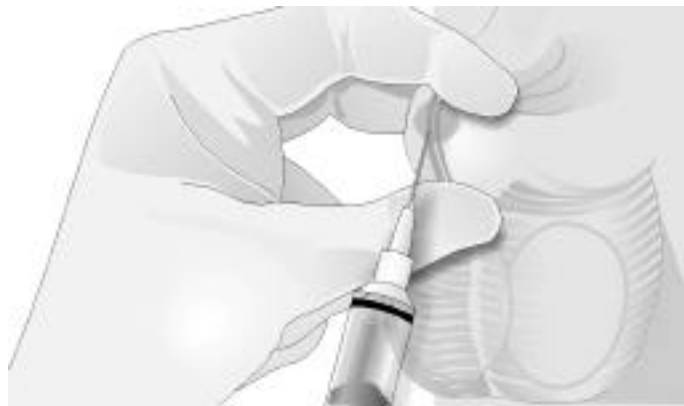

Figure 11 — Cross section, the skin wheal.





---

**TIP** — If your attempt to inject meets with undue resistance, then the needle tip has penetrated the dense wall of the vas deferens. Simply continue the gentle injecting pressure as you gradually withdraw the needle slightly. As soon as you feel the resistance relent, stop withdrawing and complete the injection.

---

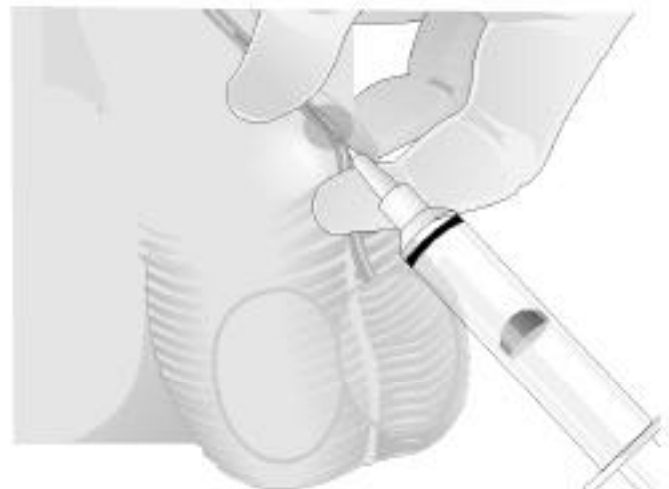
Now withdraw the needle.

At this point, change your body position by stepping slightly toward the patient's head and turning to face the patient's feet. Reach across the patient's abdomen with your nondominant hand. Extend your middle finger and place it transversely behind (posterior to) the scrotum so it points back toward yourself. Your thumb and index finger rest on the anterior scrotum, again forming a window over the site of the skin wheal (Figure 9). Palpate the left vas between your thumb and middle finger, and tense the skin with your index finger. Position the vas under the median raphe, bring the needle to the site and repeat the injection (Figure 13).

Figure 12 — The vasal block, needle position.

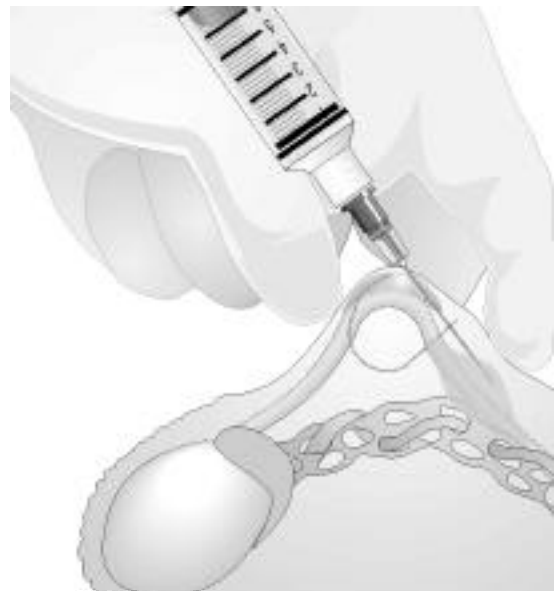

Figure 13 — The vasal block, left vas.





---

**TIP** — While you're administering the local anesthetic, put the patient at ease by anticipating each sensation and verbally predicting it. For example, "This will sting. ... You may feel burning for a few seconds" (with the wheal); "This will cause an aching up into the groin" (with the paravasal injection). The more accurate your predictions, the more enduring will be your patient's confidence and the less painful his experience.

---

The anesthetic generally takes effect over 1 to 2 minutes. Take a moment to gently compress the skin wheal between gauze in preparation for the puncture step. When you are ready to proceed, test the effect and give the patient confidence in the anesthetic by pinching the skin with an instrument and asking if it hurts.

---

# NSV Step-by-Step

Let us move to the next steps of the procedure. In this sequence, the success of each step depends upon the successful completion of each of the previous steps. A smooth operative flow is achieved by meticulous attention to detail and practice of each movement.

## Fixation of Vas

Grasp the right vas using the three-finger technique and position it under the median raphe (Figure 14a). Hold the vas-fixing forceps in your dominant hand, spread the tips, and extend your index finger to stabilize and guide the clamp. It is important to be firm and definitive when grasping the vas. While the vas-fixing forceps is designed to be atraumatic, repeated grasping efforts will certainly cause swelling and make isolation of the vas more difficult.

Trap the width of the vas with the vas-fixing forceps against the pad of your middle finger, one tip on each side of the vas (Figure 14b). Because of differences in the thickness and resistance of scrotal tissues, this may be a simple procedural step in some patients, but may be the most difficult step in others. The vas has a tendency to slip away from the tips of the forceps as they close together. Thus, once positioned, you must use a

Figure 14a — Fixation of the right vas in the vas-fixing forceps.

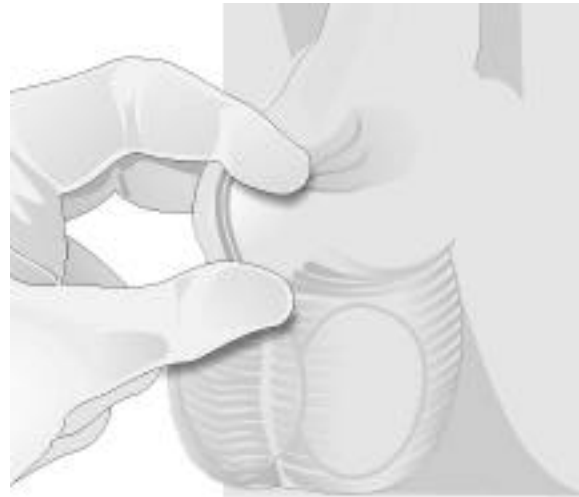
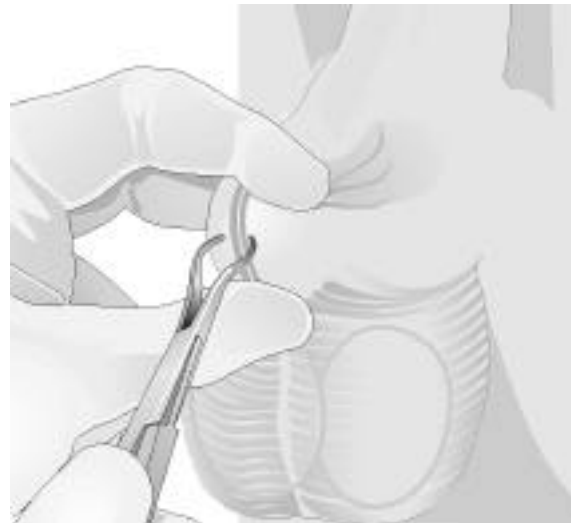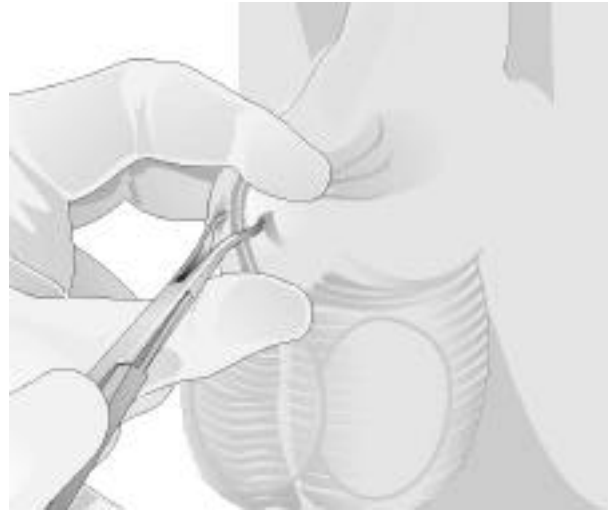


Figure 14b



great deal of pressure to keep the vas in place. Be sure to hold the tips of the vas-fixing forceps perpendicular to the skin surface. Gradually apply increasing pressure through the scrotum against your middle finger with the tips apart until you can clearly feel both tips, with the vas in between, against the pad of your finger (Figure 14c).

Figure 14c



At this point, the patient will feel the same pressure. Although his anterior scrotal skin is anesthetized, his posterior scrotal skin is still fully sensitive, so tell him what to expect. I usually say, “Now you will feel a lot of pressure as I lift the vas. The pressure will go away in three seconds.”

Maintain the pressure while you slowly close the clamp. Closing too fast can make the vas slip out of, instead of into, the grasp of the clamp. To avoid pinching the posterior skin of the scrotum between the closing tips, relax the downward pressure before locking the clamp. Review this segment in the video to observe the timing.

Once you release the pressure, the forceps can be locked, and the vas should be secure. It is unlikely that the vas will slip away once you have properly applied the vas-fixing forceps. Pause at this point and release the three-finger fixation. Lift the vas-fixing forceps and palpate the vas to ensure that it is entirely encircled by the forceps. If you find that it is only partially encircled, it is sometimes possible to unlock and adjust the vas-fixing forceps while you hold the vas between your thumb and index finger. Alternatively, you may be able to secure a second vas-fixing forceps around the vas and then release the first clamp. (If neither of these methods works, start the fixation step over again.)

When the vas is properly fixed in the forceps, the scrotal skin is tensed smoothly around the vas. To achieve this, you must choose the correct spacing of the tips as you apply the vas-fixing forceps. This will allow the skin to stretch tightly around the vas as you close the clamp and grasp the

---

vas. If you spread the clamp tips too little, the skin won't stretch around vas, and you will not be able to grasp the vas, the skin will tear, or the tips will puncture the skin. If you spread the tips too much, there will be redundant skin over the vas, making the puncture step more difficult.

---

**TIP** — As discussed on page 25 in Chapter 4, if the vas slips away laterally, it is relatively easy to grasp it again; if it slips away medially, it will usually be necessary to re-isolate it. Therefore, as you apply the vas-fixing forceps, it may help to apply more pressure to the medial tip at first, then equalize pressure on the medial and lateral tips as they close around the vas.

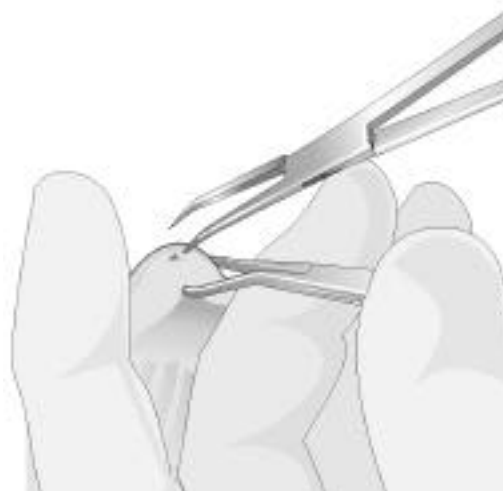---

Bring the handles of the vas-fixing forceps from a vertical to a horizontal position. Release your three-finger grasp and grasp the vas-fixing forceps in your nondominant hand. Change your grasp by moving your middle finger from behind the scrotum to just under the straight portion of the vas-fixing forceps. Your ring and little fingers are next to the middle finger and your thumb is on top of the clamp. Lift the clamp slightly to place traction on the vas. Rest your index finger beyond the tip of the clamp to help tense the scrotal skin.

### Puncture

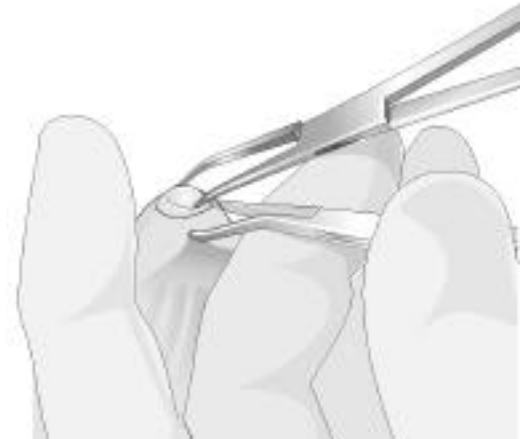The vas now forms a prominent bulge under the tensed skin. You will make the puncture at the center of this bulge, where the skin is securely fixed. Take the sharp dissecting forceps in your dominant hand and, with the tips pointing away from you, spread the tips. Align the tip that is closer to you parallel to the vas and place it against the skin (Figure 15). Visualize the course of the vas. In one smooth motion, drive the single

Figure 15 — Puncturing into the vas.



tip forward 2 mm, penetrating through the skin and into the vas. The object is to place the tip into the center of the vas lumen. Then withdraw the single tip, close the forceps and insert the closed tips together into the track you have created to the lumen. Holding forward pressure, forcefully spread the tips of the sharp dissecting forceps to a width of about 4 mm, or about twice the width of the vas. This creates an opening through all layers of skin and fascia through which the vas is visible (Figure 16). The motion usually leaves a small crack in the anterior surface of the vas; the texture of the crack can help you identify the vas. If necessary, repeat the motion to further spread the fascia and skin, but take care to avoid fraying the vas itself by reinserting the tips of the closed forceps only along the anterior surface of the vas, not into the vas.

Figure 16 — Spreading all layers of skin and fascia.



The puncture incision should gape open to reveal the vas. If it tends to fall closed each time you spread the tissues and remove the forceps, there was not enough tension on the skin created during the fixation step (i.e., the tips of the vas-fixing forceps should have been closer together on the skin before the clamp was locked).

---

**TIP** — If you cannot see the vas, add the following step: Take a second vas-fixing forceps, place the tips inside the incision, spread them just enough to encircle the vas, then lock the clamp. This depends on your tactile sense as much as it depends on your visual guidance. Check by palpation that the vas is encircled by the second clamp, then release the first clamp. You should now be able to see bare vas, even if it's only a 1- or 2-mm segment.

---

## Delivering the Vas

This step can look nearly magical to the untrained observer. The clean white vas will seem to shed the shrouds of fascia and rise, suspended by the tip of the sharp dissecting forceps. You may feel a moment of apprehension as the vas hangs precariously before being securely regrasped. There are several potential pitfalls in this step.

Begin by poising the sharp dissecting forceps over the exposed vas as you did in the puncture step, this time using the tip farther away from you. Align the tip exactly parallel to the vas and again visualize the course of the vas. Guide the sharp tip through the anterior surface of the bare vas until it just enters the lumen. Now rotate the sharp dissecting forceps around the axis of that tip 180 degrees, without moving the axis from its position parallel to the vas (Figure 17).

As the rotation proceeds, the tips of the sharp dissecting forceps will point upward. Avoid lifting the handles of the forceps; in fact, keep the handles below horizontal and lower than the tips to help effect the “hooking” of the vas by the curved tip. As your hand rotates palm-up, your wrist and forearm often must lie between the patient’s thighs to achieve the proper angle.

Figure 17a — Delivering the vas.

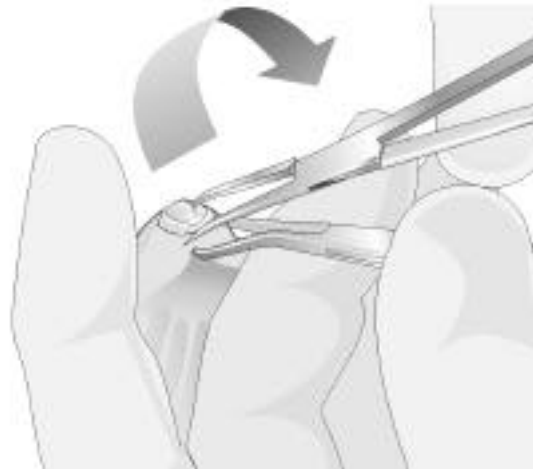

Figure 17b

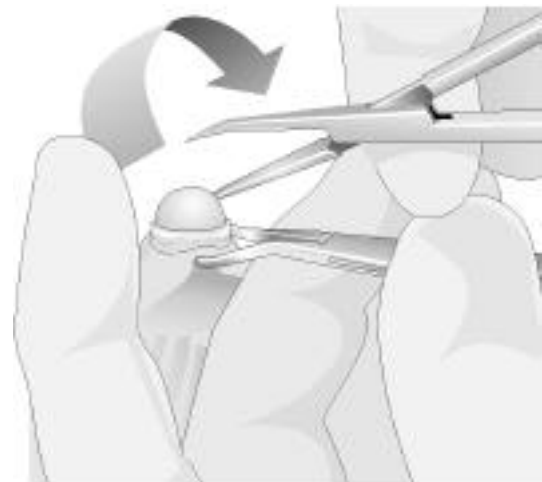


Figure 17c





---

**TIP** — To guide the sharp dissecting forceps precisely, it may help to rest the instrument on the thumb of your nondominant hand, which is on top of the vas-fixing forceps, while you align the position and angle for piercing the vas. Placing your extended index finger near the tip of the sharp dissecting forceps will give the best control over placement of the tip and the amount of traction being applied.

---

Be sure to pierce only one wall of the vas with the sharp dissecting forceps. A potential pitfall during this step is penetrating through the opposite wall of the vas with the tip of the forceps. This can cause the exposed tip to hook loose fascial tissue and prevent a clean delivery.

The exposed segment of vas is now bulging with the traction of the sharp dissecting forceps and is restrained by the grasp of the vas-fixing forceps. As you shift your hand position and your attention to releasing the vas-fixing forceps, continue to maintain the traction on the vas to keep it from slipping off the tip of the sharp dissecting forceps. However, be aware that excessive traction will tear through even the tough fibers of the vas.

Relax your hold on the vas-fixing forceps, and slide your fingers into the handles. Smoothly unlock and open the clamp and pull it aside, but do not set it down. Monitor and adjust the angle and amount of traction applied by the sharp dissecting forceps as you release the vas-fixing forceps and the vas is delivered from its sheath (Figure 18).

Next, regrasp the loop of vas with the vas-fixing forceps. This part may take some practice, since you will apply the clamp using your nondominant hand. You must avoid pushing the vas loop off of the tip of the sharp dissecting forceps. The object is not to encircle the vas, because the tips may pinch the vasal artery; instead, pinch across the diameter of the bare vas with the tips of the vas-fixing forceps while trying not to grasp the adherent

Figure 18 — Preparing to regrasp the vas.



fascia. The axis of the vas-fixing forceps is held horizontal, with the tips in a vertical plane, and the forceps approaches the loop of vas perpendicularly from the side nearest you. This allows you to see optimally, as one tip supports the inside of the loop and the other closes on top. Lock the clamp and the vas is again secure.

Withdraw the sharp dissecting forceps and reposition them to approach the loop from the side away from you.

### Dissection Method

Still holding the loop of vas upward with the vas-fixing forceps, pull the top of the loop toward you to get a better view of the far side. Use one tip of the sharp dissecting forceps to begin dissecting the fascia away from the vas. Penetrate the “window” of fascia beneath and immediately adjacent to the loop of vas. This will create a space between the vas and the basal artery, which usually courses just inside the loop. Now place the closed tips of the sharp dissecting forceps into that space and spread the tips vertically to atraumatically strip the fascia, which contains blood vessels, away from the bare vas (Figure 19).

Do not dissect more than is needed (approximately 1 cm is usually sufficient) to separate the ends of the loop of vas and create a fascial interposition. If bleeding is encountered, it may be controlled with light electrocautery at this point. Alternatively, it may be clamped with a mosquito hemostat and incorporated in the fascial suture or

Figure 19a — Stripping the fascia from the loop of vas.



Figure 19b



Figure 19c





clip. If bleeding is pulsatile, then the vasal artery has been torn and it should be separately ligated in the usual fashion with absorbable or permanent suture or a vascular clip.

Occasionally you will note blood extravasation into the fascia as the vas is delivered and before dissection of the vas loop. This is attributable to the anesthetic administration and is sometimes unavoidable, even with cautious needle placement. Fortunately, it is a minor concern and is unlikely to be a source of hematoma.

### Occluding the Vas

The no-scalpel vasectomy method ends with the presentation of the vas deferens. The vas may then be occluded in the manner that the surgeon chooses. Several acceptable occlusion methods have been widely popularized, and most can be easily used in conjunction with the NSV method. We will discuss occlusion again in Chapter 8. For this lesson, we will use electrocautery without ligation and with fascial interposition.

Proceed with electrocautery of the vas lumen. Insert the needle tip cautery approximately 1 cm into the lumen of the prostatic side of the vas loop. You may insert the needle tip through the cleft in the anterior vas wall created by the puncture maneuver, but it is also sharp enough to pierce through the intact vas wall. In either case, once the tip enters the lumen, you can feel it glide easily, indicating it is not dissecting within the wall of the vas. Start the current and withdraw the needle tip to give a progressive burn effect along the vas wall. The testicular side of the loop may be cauterized in the same manner.

Then cut the loop with scissors. Choose an avascular site toward the prostatic end of the loop. Hold the longer testicular end in the vas-fixing forceps and allow the shorter prostatic end to retract within the sheath of the vas.

### Fascial Interposition

Closing the sheath over the prostatic end creates a barrier. Sometimes the vas does not easily slide within the sheath, making closure of the fascia difficult. You may need to push it with an instrument. The sheath comprises multiple layers of thin adventitial fascia of the spermatic cord

---

and is replete with blood vessels. You should attempt to draw closed a thin veil of tissue without causing bleeding. The best way to do this is to gather the very edges of the fascia, where you can see clear spaces between vessels. You can use 4-0 chromic suture in a simple figure-of-eight or purse-string closure. A noncutting suture needle is preferred. If necessary, obtain hemostasis using light electrocautery, clips or ties.

Alternatively, you can lift the edges of fascia and clip them closed using a metal vascular clip. This is less likely to cause bleeding than the suture needle and may be faster. However, it does require a special instrument for application.

In either case, use caution not to entrap skin or dartos muscle layers in the fascial closure, as this will tether the vas to the superficial layers, causing later discomfort with motion.

---

**TIP** — You can now see the reason for not dissecting more of the loop of vas than you need. If you have pushed the fascia down too far, it may be difficult to identify the layers and gather the edges for fascial interposition. Similarly, when you deliver a perfectly clean loop of vas, free of fascia, you might be unable to effect fascial closure.

---

In yet another case, you may get the feeling that the vas will retract vigorously upon division, and that it may pull the fascia with it. In this case, wait to divide the vas until after you have passed a suture once through the edge of the fascia. Then use the suture to elevate the fascia if it retracts with the vas under the skin.

If you are unable to close fascia over the prostatic end, try closing it over the testicular end. If an appropriate segment of fascia does not present itself or if it is simply covered with vulnerable blood vessels, it is better to abandon the attempt to achieve fascial interposition than to cause trauma or bleeding.

The vas is then allowed to slip back into the scrotum and the surgeon prepares to perform the procedure on the contralateral vas.

---

## Delivering the Second Vas Through the Same Site

Now shift your body and hand positions exactly as you did to administer anesthetic to the second vas, reaching across the patient with your nondominant hand. The three-finger technique is used to secure the vas. The vas-fixing forceps is applied again, with the same technique you used for the first vas. Again, be sure to guard against allowing the vas to slip away medially, and remind the patient of the pressure he will feel as you lift the vas in the vas-fixing forceps.

Figure 20a — Fixation of the second vas through the same site.



The difference in delivering the second vas is that you center it under the existing puncture site (Figure 20). As you spread the tips of the vas-fixing forceps and apply them to the skin surface, instead of the skin tensing over the vas, it will tend to gape open, revealing the fascia tensed over the vas. It is still best to apply the tips to the skin rather than inserting them through the opening to grasp vas. Once the vas is securely locked in the vas-fixing forceps, release the three-finger grasp.

From this point on, the procedure is identical to the one used for the first vas. Reposition yourself and regrasp the vas-fixing forceps. Prepare for the puncture

Figure 20b

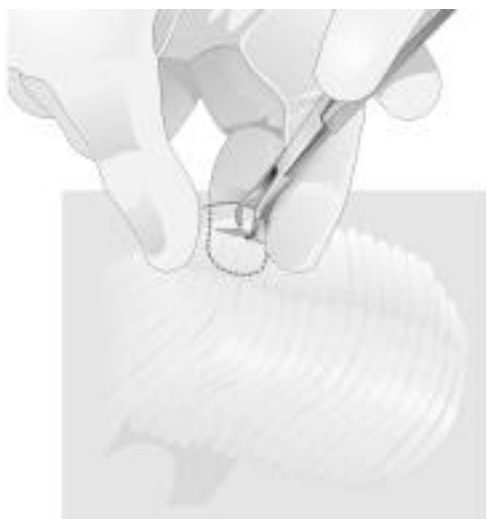
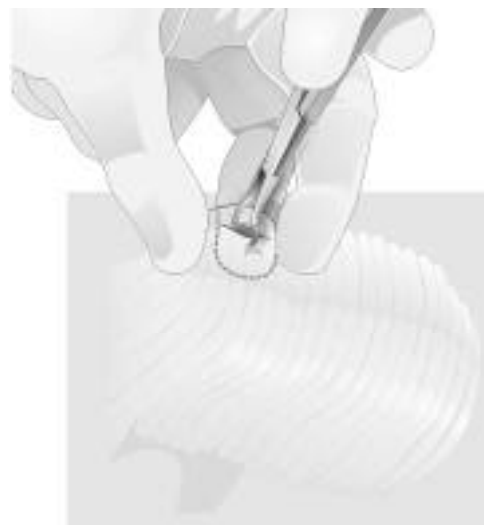

Figure 20c



step by (1) putting traction on the vas, (2) lowering the handles of the vas-fixing forceps and (3) using your index finger to tense the skin over the vas. Though the skin layer is already open, the puncture step is still important because of the multiple layers of fascia surrounding the vas. Using one tip of the sharp dissecting forceps, pierce all layers of fascia and into the lumen of the vas. Withdraw the sharp dissecting forceps and place the closed tips together into the track. Spread all layers about 4 mm to expose the vas. Deliver the vas and dissect the loop as you did before.

Anatomically speaking, a septum divides the scrotum in the sagittal plane that intersects the median raphe. However, the septum does not appear surgically as a significant structure, and for this procedure, it can be ignored.

After occluding the second vas, allow it to slip back into the scrotum. Apply pressure to the puncture site for 5 to 10 minutes by pinching it between gauze. Check the wound for hemostasis. If you have the patient wear clean, snug briefs to the office, you can simply tuck a gauze pad into the briefs, making an adhesive bandage unnecessary. No sutures are required for the small, 4-mm wound, which usually disappears in the folds of the scrotum and is well healed within 1 week.

Before the patient leaves the office, give him a printed postoperative instruction sheet to review and take home.

---

# Care After No-scalpel Vasectomy

After his vasectomy, the patient will probably be pleasantly surprised to discover that he feels quite well, and may tend to ignore his doctor's admonitions. The focus of care after vasectomy is the prevention of complications, chiefly bleeding and hematoma. The patient needs to understand that comfort alone does not indicate that an activity is safe. Due to the minimally invasive nature of the procedure, there may be little or no discomfort even after the local anesthetic has worn off. However, with activity, the disruption of tiny blood vessels in the spermatic cord can initiate bleeding. Such bleeding may be slow but persistent, perhaps because of the loose scrotal interstitium, which provides no resistance or support. The result may be extensive ecchymosis or frank hematoma.

It is well known that patient compliance with verbal instructions is poor. In order to be effective, postoperative instructions should be given both verbally and in written form. Figure 21 gives an example of written instructions for patients. The instructions should be concise, specific and clear to patients at every level of medical sophistication. Ideally, the partner will understand and help the patient follow the instructions. It is wise to set up realistic expectations for postoperative activity by giving the written instructions to the patient during the initial informational session. You may also remind him by telephone when he schedules his procedure.

The incision is usually less than 4 mm in size, and after gentle pinching at the conclusion of the procedure, it stays closed and does not require sutures. This results in rapid healing by primary intention within 1 week. If the patient washes the area too vigorously or dabs at it when applying a topical preparation, it may cause the skin edges to separate, and they may bleed. This bleeding will stop spontaneously and will quickly abate with gentle pinching for 10 minutes. If the wound is open, a scab will form and it will heal by secondary intention over 2 weeks. It is best to instruct the patient to leave the site undisturbed and to simply pat it dry gently after a shower.

---

Figure 21

## After You've Had a Vasectomy

Most patients report only minimal to mild discomfort after vasectomy. The purpose of restricting your activities is to prevent swelling, internal bleeding and complications after the procedure. Please follow these instructions and call the doctor's office if you have any questions or concerns.

### How do I take care of the incision?

- Keep the incision clean and dry for 24 hours. Showers are OK after the first day.
- Avoid taking a bath for 1 week.
- Wear snug-fitting briefs for protection and comfort during the first week.
- Keep a clean gauze against the skin for 2 to 3 days.
- If you notice that the incision is bleeding, try pinching the skin between gauze for 10 minutes.

### What activities can I do — and not do — after the surgery?

- Rest at home on the day of your surgery. After leaving the office, go straight home, relax and put your feet up.
- Place an ice pack over the scrotum for 20 minutes when you get home.
- You may return to light activities or work on the day after surgery.
- Take it easy for 7 days: avoid heavy lifting, contact sports and other vigorous activity. Strenuous activity might cause swelling or bleeding.
- Do not ejaculate for 7 days. After this time, you may return to your usual sexual activity, **BUT YOU MUST USE SOME OTHER METHOD OF BIRTH CONTROL.**

### What normally happens?

- A small amount of blood or other discharge may seep from the incision. This is normal.
- You can expect some mild aches and pains for a few days. The pain should not interrupt your sleep. It usually goes away within 1 week.
- A black-and-blue color around the scrotum and the base of the penis might appear on the second or third day. This is normal. It shouldn't cause any pain and will fade over several days.

### What medicines can I take?

You can take the following medicines to help with any pain. Follow the directions given on the bottle to figure out how much you should take.

- acetaminophen (brand name: Tylenol)
- aspirin
- ibuprofen (brand names: Advil, Nuprin, Motrin)
- naproxen sodium (brand name: Aleve)

### When should I call the doctor?

If you notice any of these signs, call the doctor right away:

- Severe pain.
- Excessive bleeding, forming a spot on the gauze that's larger than a 50-cent piece.
- A lump in the scrotum that feels like it's getting bigger.
- A lot of redness or pus around the incision.
- A fever above 101°F.

### When can I stop using other forms of birth control?

- Do not rely on the vasectomy for birth control until your doctor tests your semen to make sure that the vasectomy was a success.
- After 6 weeks and at least 15 ejaculations, bring in a sample of your semen to be tested.
- Semen samples can be accepted for up to 24 hours after collection, as long as you refrigerate the specimen overnight.

### Contacting the doctor

- If you have any questions or concerns, please call the clinic to schedule a follow-up visit.
- **IF YOU NEED TO REACH THE DOCTOR, CALL \_\_\_\_\_.**
- A doctor is available for emergencies 24 hours a day.

After the first day, activities most likely to cause bleeding or swelling are those that cause some stretching or jostling of the scrotum, such as stooping, climbing and jumping, or cause venous engorgement due to the Valsalva maneuver, such as lifting, pushing or straining. A lifting limit of 40 pounds without bending or straining is reasonable for the first week. This allows the patient to help with babies and toddlers, beginning on the second day.

Those who work at a desk or bench can usually return to work without risk and with minimal discomfort the day after the no-scalpel procedure. Laborers who do not have light-duty work available to them should not return to work for 1 week. After 1 week, heavy activity could result in mild discomfort, but the risk of inciting complications has passed.

Since pain after vasectomy is usually minimal to mild, nonsteroidal anti-inflammatory drugs (NSAIDs), such as naproxen sodium (Aleve, Anaprox) and ibuprofen (Advil, Motrin, Nuprin), are recommended if needed. Extra strength acetaminophen is an alternative, especially for those intolerant to NSAIDs.

Most patients do not require prescription pain medicine. In fact, stronger pain may be an important sign of a complication, which should be reported. If a patient requests a prescription, one option is to write the prescription and ask the patient to call you before taking the medicine to discuss his symptoms.

Your instructions should include abstaining from ejaculation and even sexual arousal for the first week. This is a general guideline intended to reduce the incidence of symptomatic sperm granuloma, as well as to alleviate a natural curiosity or the pressure to “try it out” before the patient is adequately healed.

### Semen Testing and Contraception

Semen testing is advised for all patients, though compliance is not very good (between 50 percent and 60 percent of patients actually submit a sample for testing).<sup>5,6,7</sup> The number of failures detected by testing is arguably quite small, about 3 per 1,000.<sup>8</sup> However, when cases of early failure are detected and corrected, it is estimated that the pregnancy rate can be reduced to roughly 1 in 2,000 patients per lifetime.<sup>9</sup> Therefore, all patients should be made aware of the benefit of semen testing.

Semen testing may be done in the office or sent to a laboratory. Be sure the lab knows to test only for confirmation of azoospermia following

---



vasectomy so that more elaborate and expensive tests for infertility are not performed. The patient should collect the specimen in a clean container by masturbation or withdrawal. (Remind the patient that withdrawal is not an effective means of birth control and to continue using another birth control method.) Collecting semen in a condom does not work well for this test because of potential contamination, dilution and handling problems.

Sperm do not readily disappear from semen in storage, although they can be obscured by bacterial overgrowth, agglutination, crystals and particulate matter. An uncontaminated semen specimen in a clean, sealed container will generally be acceptable for reading 24 hours after collection, longer if the specimen is refrigerated. Allowing the patient to hold the specimen in the refrigerator overnight and to deliver it to the office at his convenience improves the compliance with testing. While sperm motility cannot be determined in a delayed or refrigerated specimen, most criteria require absent or nearly absent sperm for clearance.<sup>10</sup> The frequency of rare sperm, which constitutes reason for retesting, is as much a matter of comfort level of the physician as it is of consensus.<sup>11,12,13</sup> Some physicians require a second specimen in all cases, probably more to reduce the risk of lab error than sampling error.

Between the time of vasectomy and a successful test, couples should continue their prior method of contraception. The sperm concentration falls an average of 60 percent with each ejaculation after vasectomy, improving the efficacy of any method.<sup>14</sup> However, based on the residual sperm concentrations, a significant risk of pregnancy exists for those who abandon contraception immediately after vasectomy. All patients should be cautioned to continue contraception until the physician advises them to stop.

### Follow-up Phone Call

A follow-up phone call 24 hours after the procedure contributes greatly to postoperative care. This call helps you determine that the patient is heeding your advice to “take it easy,” and provides an opportunity to answer questions, address concerns, reinforce instructions and reassure patients and partners of your continuing support. It also provides the physician with feedback and data on outcomes. Document this phone call in the patient’s chart. The call takes less time than an office visit, and can be made by the physician or a staff member even when the office is closed. Improved patient satisfaction is always a practice-builder.

---



## Chapter 7

# Patient Concerns

### Counseling and Informed Consent

One of the most important parts of vasectomy is the decision-making process, including counseling and informed consent.

The family physician is in an ideal position to counsel a couple who is considering vasectomy. However, patient counseling may be a combined effort of the physician and his or her staff. Those involved in the process should have refined interviewing skills and specific training.

Thorough discussions of counseling the vasectomy patient and of informed consent are beyond the scope of this package. Resources are available on counseling for family planning and for sterilization (Table 7).

It is strongly recommended that printed information, including information on preoperative preparation and postoperative care, be provided to the patient far enough in advance that he may review it, and may share it and discuss it with his partner. Some couples may not complete their discussion process for months; therefore, it is important that they have the written material to refer to.

Review the information verbally during the interview with the patient, using anatomical diagrams. Give the patient an opportunity to ask questions and address other concerns. You can gain a measure of patient

**Table 7**

#### **Resources for Counseling for Family Planning and Sterilization**

The following are helpful sources of materials for counseling patients on family planning and sterilization:

- The article "Vasectomy Counseling," by Jeanne M. Haws, M.P.A. and Joel Feigin, M.D., appeared in the October 1995 issue of **American Family Physician**.
- Two publications, "Family Practice Counseling: A Curriculum Prototype" and "Informed Consent and Voluntary Sterilization: An Implementation Guide for Program Managers," are available from EngenderHealth International. See the "Resources" section on page 69 for ordering information.

understanding through interaction with the patient and/or gentle questioning. You and your staff must ensure that the patient and his partner are fully aware not only of the risks and benefits of vasectomy, but also of the contraceptive alternatives available to them. Occasionally patients feel compelled to have a vasectomy because of misconceptions about temporary contraceptive alternatives.

The setting and the time allotted to the interview should lend comfort to the process and provide a supportive, nonthreatening environment in which a patient can discuss his situation openly. The patient should feel free to decide not to have a vasectomy if it is not the right choice or the right time for him.

A common pitfall in counseling is asking a patient only yes-or-no questions. These types of responses may not reveal much about his preparedness. The open-ended question is a useful tool. You may gain insight into the depth of the patient's decision-making process and his maturity by his responses. Having the spouse or partner participate in the interview is helpful both for the assessment of the couple's commitment to permanent sterilization and for the education of the partner.

The patient should be able and willing to discuss questions such as the following:

- “Why did you choose vasectomy?”
  - “What made you decide to consider having a vasectomy at this time in your life?”
  - “When did you and your partner start talking about this decision?”
  - “If you lost your partner in an accident, or if your relationship otherwise ended, do you think you would want to have more children?”
  - “If you lost your child(ren) in an accident, do you think you would want to have more children?”
  - “How does (partner's name) feel about your vasectomy?”
  - “What do you think your partner would say if I asked her how she feels?”
  - “How do you feel about your partner's uneasiness with your decision?”
  - “How do you think your partner will react if you go ahead with your vasectomy?”
  - “What effect do you think a vasectomy will have on your lovemaking?”
-

If the patient is divorced or single, you may need to find out if he has a steady partner. Emphasize that vasectomy is only for the prevention of pregnancy and the need for condoms to protect against sexually transmitted diseases is still relevant.

If language creates a barrier to effective communication, an interpreter should participate during the interview, and possibly during the procedure.

A patient who is unwilling to participate cooperatively in the preoperative interview should cause alarm. If, after assurance of confidentiality and attempts to establish rapport, a patient is reluctant to talk about vasectomy, his relationship with a partner or his decision, it is highly likely that he has serious reservations or significant emotional conflict that should be addressed. This patient is at risk of regret or resentment. It may be best to defer an offer of surgery to this patient, regardless of the assurance that his decision is final.

If, for any reason, you feel that a patient who has presented for vasectomy may not be competent to make this decision, it may be reasonable to seek the opinion of the patient's primary care physician, or another clinician who knows him well.

Remember that you are not obligated to provide this elective surgery in any setting in which you have reservations about the outcome, either surgically or emotionally.

### Health Risk Considerations

Does vasectomy have any long-term adverse health effects? The question naturally arises when the procedure is discussed. The brief answer is that there is no conclusive evidence that vasectomy causes any long-term health problems.<sup>4</sup> However, there are biologic changes brought on by vasectomy and it is reasonable to question whether any of these has an effect on health.

Studies have addressed vasectomy's effect on overall health, including specific topics such as heart disease and prostate cancer.<sup>15-29</sup> It is beyond the scope of this package to present the data, but readers may wish to critically review some of the published studies or the summary articles and editorials.

---

You may find that the occasional patient will request references on these topics or ask your opinion on information he has already collected.

Histologic changes occur in the testicle and epididymis following vasectomy, and include thickening of the walls of the seminiferous tubules, interstitial fibrosis in the testis and dilation due to stasis in the epididymis. These microscopic findings on biopsy do not appear to correlate with the presence of antisperm antibody in men with vasectomy.<sup>30</sup>

Vasectomy does not change serum levels of gonadal hormones or alter the pituitary-testicular axis. Beyond the disappearance of sperm, vasectomy also effects change in the composition of the semen, perhaps through an altered hormonal influence on the secretions of the seminal vesicle and the prostate. These changes are reversible with vasovasostomy and have no apparent implications for sexual function or health.<sup>31</sup>

There is an immune response to vasectomy. This can be seen in measurable serum antisperm antibodies, which are present in 70 percent of men after vasectomy, compared with about 30 percent of men without vasectomy.<sup>30,32</sup> This reflects the increased rate of antibody labeling of sperm for resorption within the testes and epididymides following vasectomy. Short-term circulating immune complexes have been reported in some studies, but they appear not to be present in the long-term and to have no significance in humans.<sup>32</sup>

In 1978, the hypothesis was advanced that circulating immune complexes induced endothelial damage, advancing atherosclerosis in a small monkey species.<sup>15,32</sup> (The story that spread widely through the lay press, combined with speculation about implications for humans, fostered widespread apprehension that occasionally persists today.) Repeat studies could not reproduce the initial findings and there is no support for concerns about increased atherosclerosis or coronary heart disease after vasectomy.<sup>18,33-35</sup>

Some epidemiologic reports of a weak increase in relative risk of prostate cancer in men with vasectomy have been criticized for methodologic faults, which included selection bias and detection bias.<sup>22,36</sup> Other large studies with long-term follow-up have showed no increase in prostate cancer.<sup>20,21,26</sup>

---

A systematic review of the literature in 1998 found no causal association between vasectomy and prostate cancer. Men with vasectomy are not at higher risk for prostate cancer.<sup>29</sup>

Overall reassurance about health after vasectomy was provided by a large, long-term case-control study, which concluded there is no association of vasectomy with increased cardiovascular mortality, overall cancer mortality or all-cause mortality.<sup>19</sup> Studies examining the health risks of vasectomy are ongoing.

### Sedation and Analgesia

Some degree of apprehension about the discomfort of the procedure is common among patients. Most patients, however, tolerate the procedure well with gentle reassurance and only local anesthetic. It is appropriate to discourage sedative use, because patients routinely overestimate their difficulty with the procedure. In my experience, most patients who think they will need sedation or general anesthesia and who proceed without it feel that they had made the right decision.

For the patient who is convinced he needs something to help calm him, an oral dose of alprazolam (Xanax, 0.5 to 1.0 mg) or diazepam (Valium, 10 mg) taken 1 hour before the procedure will likely have the desired effect. The patient and a responsible driver must understand that the patient must not be allowed to drive or sign informed consent under the influence of this medication.

Some physicians prefer to use an established protocol for intravenous (IV) conscious sedation for some or all patients who undergo vasectomy. In addition to patient comfort, there may be a benefit of reducing syncope from vasovagal episodes, and the sedation may also help relax scrotal muscle tone. Conscious sedation requires extra staff time for preparation, administration and recovery, as well as appropriate equipment for monitoring and resuscitation. It adds specific risks and costs to the vasectomy procedure; physicians who wish to use conscious sedation and who are not current in their skills may want to pursue further training. While IV sedation may be valuable for selected patients, it is probably not needed for the majority of vasectomy patients.

---

Parenteral atropine (0.4 mg) can be a useful adjunct for reducing the likelihood of severe bradycardia and syncope with vasovagal reactions, especially in a patient with a prior history of fainting during procedures.

Preoperative analgesia is not routinely used. In fact, patients are cautioned against using aspirin for 2 weeks and NSAIDs for 48 hours prior to the procedure because of their adverse effect on platelet function.

Postoperative analgesia is discussed in Chapter 6.

---

# Vas Occlusion Options

Occlusion of the vas by means of electrocautery is described in Chapter 5. You will want to decide on a method of occlusion that you can use consistently. Some traditional methods are as simple as dividing the vas and leaving the ends unaltered. A drawback to this method is that the ends may reunite more easily. Also, sperm could leak from the testicular end of the vas, evoking an inflammatory response, and a sperm granuloma could develop. If the sperm subsequently gained access to the prostatic end, it might reappear in the semen and result in pregnancy.

Ligating one or both ends of the vas with permanent (silk) or absorbable (chromic gut, polyglycolic acid) suture would seem to add a measure of security against sperm leakage or vas reunion. However, effective ligation of the vas, in contrast to ligation of a blood vessel, is difficult to achieve. This may be because of the thickness of the vas wall and the small caliber of the lumen. It's also possible that the suture tension needed to sufficiently compress the vas and block the lumen would be enough to either cut through the vas or cause necrosis of the tip of vas, which could result in the tip sloughing off. In either case, there would be a free end of vas that would be more likely to reunite or recanalize. (Recanalization is a process whereby sperm cells reach the prostatic end of the vas by traversing tiny connections from the testicular end, without the two ends actually reuniting or even touching. The histologic appearance is that of multiple microscopic channels with sperm within them.)

## Cautery

Cautery can be used to create a more effective closure. It is important to note that more extensive cautery does not give a better result. The objective is to create a burnlike injury only to the mucosa of the vas, without devitalizing the muscular layers. The desired final effect is scar formation blocking the lumen. This depends on the ability of fibroblasts to migrate into the lumen from viable surrounding tissue.

---

A cautery tip is inserted into the lumen a distance of 1 to 1.5 cm. The tip is gradually withdrawn from the vas as cauterization takes place over a few seconds. The result is a gradient of injury to the mucosa that increases toward the cut end of the vas.

There are two types of cautery: electrocautery and hot wire cautery. With electrocautery, an electrical current passes through the electrode tip and dissipates into the tissues, creating heat in the tissue proportionate to its electrical resistance. The heat causes coagulation of proteins in the tissue, which causes a change in color and/or translucency. Thus, we see the vas change from a translucent, whitish-gray color to a slightly opaque white. It should not turn brown, as this indicates excessive heat has been applied. There may be a spark as the needle is withdrawn, and a small trace of smoke may rise.

There are many makes and models of electrocautery units. A unit that works for hemostasis in office surgery will work for vasectomy. It is important to find a tip that will slide properly into the vas lumen. A sharp and stiff needle tip is best, since you can directly pierce the wall of the vas loop and guide it into the lumen (Figure 22).

A blunt wire electrocautery tip may work well if you expose the lumen first. This can be accomplished by dividing the vas with scissors, but there

Figure 22 — Electrocautery with a needle tip electrode.



is some risk of losing hold of the severed end, which could retract into the sheath before you have a chance to cauterize it. If this happens, it is acceptable to forego cautery on the end that you've lost, rather than performing extensive dissection to retrieve it. A useful instrument for holding the free end of the vas is an Adson forceps with suture platform. Another option is to hemitransect the vas with a blade or a sharp pair of iris scissors, exposing the lumen while retaining control over the loop of vas (Figure 23). After cautery, you can simply complete the transection and let the vas retract.



With hot wire cautery, the loop of wire that forms the tip is a heating element. Current heats the wire, and the wire heats the tissue by contact. The intended effect is the same as with electrocautery, but it may take less than 1 second of contact with some hot wire units. These are usually available as sterile, single-use, disposable units with self-contained batteries. Be sure to use the narrow and elongated tip (approximately 1 mm x 10 mm), as the blunt tip will not fit into the vas.

Convenience and portability are advantages of hot wire cautery. While there is less setup cost than with electrocautery, there is an additional cost of supplies and disposal. There are reusable hot wire units which have replaceable tips and batteries, but also require some method of maintaining sterility, such as enclosing in a sterile sheath or sterile glove. Hot wire cautery is good for cutting tissue and may be used to hemitransect the vas; however, it is poor for hemostasis, as it tends to stick to the tissue.

### Open-Ended vs. Closed Vasectomy

Most surgeons occlude both ends of each vas, believing that this will decrease the chance of vasectomy failure. There has recently been some controversy surrounding the question of whether to occlude the testicular end of the divided vas or leave it open. At issue is the frequency of complications and of failure.<sup>37</sup> Specifically, there is a hypothesis that pain due to congestion in the epididymis and testis following vasectomy (congestive epididymitis, orchialgia) may be less likely to occur when the testicular end of the vas is left open.<sup>38-40</sup> The premise behind this hypothesis contends that occluding the vas causes a backup of pressure and that this pressure can cause pain. Leaving the testicular end of the vas open may also release more pressure and sperm into the scrotal tissues. If this hypothesis is correct, we would expect to see less epididymitis in cases where the testicular end of vas was left open, but would also see the potential for more symptomatic sperm granulomas. That said,

Figure 23 —Hot loop cautery through the hemitranssected vas.



concern has been raised about an increase in vasectomy failures due to recanalization when the testicular end of the vas has been left open.<sup>41</sup>

A randomized study comparing open-ended and closed vasectomy has not yet been published. Because both complication rates and failure rates are low, it may be difficult to detect a definite advantage between the open and closed techniques without a randomized clinical trial. Preliminary analysis of an unpublished randomized study in which the author is the lead investigator with over 2,000 patients has failed to support any significant difference in outcomes.

Pending more conclusive evidence, one can expect to have similar excellent outcomes when the testicular end of the vas is either left open or occluded in some way.

### Fascial Interposition

Creating a barrier of fascia between the cut ends of vas is described in Chapter 5. This step may be the most valuable in reducing recanalization risk.

### Excising a Segment and Pathology Specimens

There is reason to reconsider the common practice of excising a short segment of vas, since it probably does nothing to improve outcome. The gap that the excision forms can be easily bridged by the redundant length of the vas. Studies show that failure rates improve only if a large segment (4 cm or longer) is removed. Doing so would require significantly more dissection and would add risks of bleeding, hematoma and discomfort. It also would make vasovasostomy virtually impossible.<sup>42</sup>

Pathologic evaluation of a specimen of vas can be reassuring in unusual cases, such as a diminutive vas size or a convoluted vas. In typical cases, however, I believe there is little or no value in receiving a pathologist's report confirming vas deferens, nor in saving two bits of tissue in a bottle for possible future examination. Since many failures are due to recanalization, the histology of the specimens is not predictive and can even give false reassurance; a follow-up semen test is more reliable.<sup>43</sup>

In summary, then, I recommend occluding the vas by intraluminal cautery (either hot wire or electrocautery) of the prostatic end or of both ends, combined with fascial interposition.

---

# Management of Complications

Complications generally occur in less than 10 percent of vasectomy patients.<sup>44</sup> Although the majority of these complications are minor and self-limited, the manner in which the physician manages these problems largely affects patient satisfaction and the reputation of one's practice in the community, and can influence public acceptance of the procedure.

Conventional wisdom says that one good experience is shared with one other person, and one bad experience is shared with 10. Even the patient who has experienced a complication may consider his overall experience a good one if he and his family perceive that he has been treated especially well despite the problem.

Major complications are rare enough that most physicians who perform vasectomies have little or no experience in managing them. Table 8 presents some principles of management suggested to optimize outcome. A decision to **obtain consultation early** in the case is more likely to generate support than criticism from most consultants and most patients. Even in cases of infections and large hematomas, permanent morbidity will likely be averted if appropriate management is promptly instituted.

Being prepared to handle a complication is the first step: **Have a plan. Arrange expert backup:** Know whom you will choose to consult if needed, usually a trusted urologist. Talk with this consultant at a convenient time and explain your decision to offer vasectomy to your patients. Request that he or she accept referrals of patients whose exam suggests that surgery will be difficult. Ask the consultant to be available should you have problems or complications. He or she

Table 8

### Managing complications

- **Get consultation early**
- **Have a plan**
- **Arrange backup**
- **Be available**
- **Respond promptly**
- **Implore your patients to call promptly if they think they have a complication**
- **Communicate openly**

may also be willing to serve as a preceptor for a few cases. Be sure that the physicians who take calls for you after hours and those in the consulting group are aware of your arrangement.

**Be available:** Be sure you are aware of and **respond promptly** to your patients' problems. This can be emphasized during the follow-up phone call done in the first 24 hours after the procedure. **Implore your patients to call promptly** if they think they have a complication. Respond promptly to these calls.

**Communicate openly:** Talk with the patient often enough to hear his concerns. If a complication presents itself, it is very important to tell the patient what the problem is, how it may have occurred and what to expect from it. Review his options for intervention and tell him what you recommend. Most important, communicate that you care. Let the patient and his family know that you are committed to helping him through to good health, even if others are involved in his care. You can make a patient feel special and build trust by giving him special access to you with the number to your pager, cell phone, personal line or home. At the very least, tell your receptionist to recognize him and his partner when they call.

### Congestive Epididymitis

Because of the early onset and spontaneous resolution of congestive epididymitis, many consider it to be a normal part of recovery and not a complication. However, the course is distinctly different from that of the average recovering patient, so it can be recognized as a separate entity.

Symptoms of congestive epididymitis include pain and tenderness in the epididymis with radiation to the groin. There may be a small amount of focal swelling in the head, body or tail of the epididymis. Swelling is usually unilateral. There is no fever. Onset is 3 to 5 days following vasectomy. The condition appears to be an inflammatory response presumably caused by congestion, not infection, in the epididymis. It responds within 48 hours to oral NSAIDs and usually resolves in 7 to 10 days with or without treatment.

Congestive epididymitis can usually be managed over the phone. Talking the patient through a self-examination of the tender area may reassure him of the diagnosis.

---

Anecdotally, proposed preventive measures, including prophylactic NSAIDs or antibiotics, early ejaculation after vasectomy, and open-ended technique, do not seem to prevent this complication.

## Sperm Granuloma

Clinically, sperm granuloma may present as a tender nodule, a few millimeters in diameter, at the site of vas division or at another site along the vas or in the epididymis. It may appear at any time after ejaculation has resumed. If the granuloma is not tender, the patient may be unaware of it. In fact, according to findings at vasovasostomy, asymptomatic sperm granuloma may almost always be present.<sup>40</sup>

Whether macroscopic or microscopic, sperm granuloma is, histologically, a foreign body reaction to sperm leaked from a disruption of the genital tract. While it is common for sperm to leak at the site of vas division, there are also spontaneous ruptures in the epididymis that can produce sperm granulomata.

Patient reassurance is usually all that is required. NSAIDs offer relief of any bothersome tenderness. Typically, discomfort diminishes over time, and intervention is usually not necessary. Rarely, the nodule will need to be surgically excised.

Of greater concern is the possible association between sperm granuloma and vasectomy failure resulting from recanalization. If the granulomatous inflammation spreads to involve the prostatic end of the divided vas, it is thought to be more likely that a connecting channel could form, restoring sperm transmission along the vas deferens.<sup>39,45</sup>

The practice of prohibiting sexual arousal and ejaculation in the first week after vasectomy is based on the presumption that sperm leakage through the immature scar at the cauterization site may stimulate sperm granuloma. Useful data on this issue seem to be lacking, and many physicians allow early sexual activity within limits of comfort.

## Neuroma

A neuroma, or a tender nerve ending buried in scar tissue where a sensory nerve was inadvertently damaged or severed during surgery, can be found

---

in a very small number of patients following vasectomy. The patient may be very concerned or alarmed, but reassurance is usually all that is needed, as neuromata rarely present enough discomfort to interfere with normal activity.

## Prostatitis

Patients who have undergone vasectomy may develop acute prostatitis, possibly due to stasis and congestion of the prostate during the period of abstinence following vasectomy. Standard treatment for prostatitis applies.

## Postvasectomy Pain Syndrome

Although mild discomfort in the area of the testicles is occasionally noted by patients after vasectomy, persistent significant discomfort is rare. Chronic pain management may be enhanced by a multidisciplinary approach, which can include urologic evaluation, psychological support and pain clinic medication regimens. Surgery has provided little if any benefit to patients with postvasectomy pain syndrome.<sup>46,47</sup>

## Infection

Infection at the scrotal incision is rare, probably because of the excellent vascular supply and the minimal trauma of the puncture technique. Meticulous sterile technique and antiseptic preparation also can reduce the risk of infection.

A minimal wound infection with colored discharge can usually be managed safely in the outpatient setting; however, if there is any induration or cellulitis, if the area is fluctuant, or if signs and symptoms of systemic infection are present, hospitalization for parenteral antibiotic treatment is necessary.

Cellulitis and deep infection can lead to gangrene and septic complications in the worst cases. Tissue trauma during surgery with necrosis due to excessive cautery, clamping or suture strangulation creates an opportune setting for infection. Bleeding and hematoma contribute substrate and space for abscess formation. The risk of infection can be minimized by gentle tissue handling, minimal cautery and careful hemostasis. The length of operating time correlates with incidence of infection. NSV can be completed in 5 minutes; in most cases, it will not exceed 20.

---



## Hematoma

Hematoma is not just ecchymosis, but a mass, generally larger than a grape. It occurs when a vessel continues to bleed into the loose tissue of the scrotum. Hematomas can arise simply from the administration of local anesthetic, though these are usually trivial. Large hematomas most likely result from unrecognized damage to the vasal artery. Close inspection for bleeding along the vas, especially after relaxing the constriction of the skin opening, helps prevent this complication. Avoid cautery on the vasal artery in favor of clips or ligation.

A large hematoma may require surgical evacuation with drain placement, but only if it occurs within the first few hours, is tense and enlarging, and does not stabilize with ice packs and elevation. Drainage may help resolve the problem quickly, but may increase patient discomfort in the short term. Large hematomas typically evolve into seromas, the mass of which can cause discomfort, but these will gradually resolve on their own.

## Failure

When failure occurs, it is almost always due to a recanalization that occurs during the initial weeks of healing.<sup>48</sup> Examination should include a careful search to exclude a third vas deferens. If no third vas is found, the NSV procedure can be repeated. The procedure is easiest if one selects a new division site on each vas, either superior or inferior to the previous one.

---

## Clinical Outcomes of Vasectomy

Among all elective surgeries, vasectomy must be considered one of the best in terms of successful outcomes and safety from complications and adverse effects. Surveys of vasectomy patients have recorded high levels of satisfaction, about 95 percent.<sup>49</sup> NSV helps to maintain and improve this record, which is important to public perception of vasectomy and its role among contraceptive methods.

Data presented in this chapter may be useful to the patient who requests such information.

### Failure Rates

Vasectomy failure depends mostly upon the method of occlusion used, and is generally reported to range from 0.02 percent to 1.66 percent.<sup>42,50</sup> As such, the NSV technique does not appear to affect the failure rate. Table 9 presents a summary of failure rates of vasectomies performed by several doctors using various techniques and categorized by the method of occlusion. We discuss occlusion methods further in Chapter 8.

Table 9

### Vasectomy Failures by Occlusion Method

METHOD	N	FAILURES	%
<b>Ligation</b>	<b>3075</b>	<b>48</b>	<b>1.6</b>
<b>Cautery plus Ligation</b>	<b>600</b>	<b>10</b>	<b>1.66</b>
<b>Clips</b>	<b>569</b>	<b>2</b>	<b>.35</b>
<b>Electrocautery</b>	<b>3700</b>	<b>10</b>	<b>.27</b>
<b>Large excision</b>	<b>4641</b>	<b>0</b>	<b>0</b>

*Adapted with permission from Denniston GC. Vasectomy by electrocautery: outcomes in a series of 2,500 patients. J Fam Pract 1985;21(1):35-40.*



When considering failure rates with vasectomy, it should be noted that not all failures result in pregnancy. Reported failure rates usually include all technical failures, meaning those in which sperm reappear in the semen. Pregnancy can be avoided in most of these failures by semen testing and a repeated vasectomy. Of men who have passed a semen test, the incidence of late failure of a successful vasectomy (manifested either as a pregnancy or as a positive semen test subsequent to a negative semen test) is less than one-tenth of 1 percent (0.1 percent) per lifetime.<sup>10,51</sup>

Failures of other methods of contraception are usually reported as rates of pregnancies per 100 women per year. For example, oral contraceptives fail in about 5 percent of women per year of use, and condoms fail in about 14 percent.<sup>52</sup> Tubal sterilization has a failure rate of at least 0.75 percent per 10 years.<sup>53</sup>

## Complications

Surgical complications may be considered in two categories. Major complications are those that cause serious morbidity or time lost from work. These complications are almost exclusively related to hematoma or infection. Complications requiring hospitalization or surgical management are rare.<sup>54</sup> Testicular necrosis due to compromise of the testicular artery may be a concern if excessive surgical manipulation, ligation or cauterization was necessary. Deaths related to vasectomy are rare, but have occurred when management was delayed or neglected and serious infection ensued.<sup>55,56</sup>

Minor complications are self-limited and do not cause time lost from work. Most of these are related to congestive epididymitis or sperm granuloma. Others causes are neuroma, dermatitis, thrombosed varix and medication reaction.<sup>54,55</sup>

Table 10 presents some published data on complication rates in traditional vasectomy and NSV.

Table 11 presents unpublished data on outcomes of NSV performed by the author.

---

Table 10

## Vasectomy Complications — Incidence by NSV or Incisional

SERIES	N	INCISIONAL			NSV		
		Complications %	Hematoma %	Infection %	Complications %	Hematoma %	Infection %
Penna et al (1)	843	5.9	0.5	1.5			
Alderman (2)	1224	10.6	0.33	3.9			
China series (3)	179,741					0.09	0.91
Goldstein, N.Y. (3)	238					0	0
Mexico Family Planning (4)	1000				2.1	0.2	0
King's Birthday Vasectomy Festival, Thailand (5)	1203						
Incisional	523	3.1	1.7	1.3			
NSV	680				0.4	0.3	0.1
Sokal et al (6)	1429						
Incisional	723	13.7	12.2	1.5			
NSV	705				2.0	1.8	0.2
Alderman and Morrison (7)	619						
Incisional	283	4.2	0.3	0.7			
NSV	336				3.9	0.3	0.6

1. Penna RM, Potash J, Penna SM. Elective vasectomy: a study of 843 patients. *J Fam Pract* 1979;8:857-8.
2. Alderman PM. Complications in a series of 1224 vasectomies. *J Fam Pract* 1991;33(6):579-84.
3. Li SQ, Goldstein M, Zhu J, Huber D. The no-scalpel vasectomy. *J Urol* 1991;145:341-4.
4. Arellano Lara S, Gonzalez Barrera JL, Hernandez Ono A, Moreno Alcazar O, Espinoza Perez J. No-scalpel vasectomy: review of the first 1,000 cases in a family medicine unit. *Arch Med Res* 1997;28:517-22.
5. Nirapathpongorn A, Huber DH, Krieger JN. No-scalpel vasectomy at the King's birthday vasectomy festival. *Lancet* 1990;335:894-5.
6. Sokal D, McMullen S, Gates D, Dominik R. A comparative study of the no scalpel and standard incision approaches to vasectomy in 5 countries. The male sterilization investigator team. *J Urol* 1999;162:1621-5.
7. Alderman PM, Morrison GE. Standard incision or no-scalpel vasectomy? *J Fam Pract* 1999;48:719-21.

Table 11

## No-scalpel Vasectomy Outcomes — Wilson

	Number	%
<b>Total N=2600</b>	<b>2600</b>	<b>100</b>
<b>Failure</b>	<b>8</b>	<b>0.3</b>
Pregnancy	1	.04
<b>Complications</b>	<b>173</b>	<b>6.7</b>
Hematoma	1	.04
Infection	0	0
Epididymitis	134	5.2
Sperm Granuloma	27	1.0
Other	13	0.5

### Pain or Discomfort

Patients need to know what to expect from NSV, but the perception of pain is so unique to each individual that one cannot predict what a given patient will experience. However, it is possible to make some generalizations based on experiences reported by recent patients.

Pain associated with vasectomy can be divided into pain during the procedure, pain during recovery, and chronic or persistent pain.

A total of 250 patients who had recently undergone NSV completed a survey mailed by my office. Recipients were asked to rate their pain or discomfort during the procedure and during recovery. In summary, pain or discomfort during NSV were associated primarily with the administration of local anesthetic and were rated mild or less than mild in 83 percent of patients, moderate in 14 percent and severe in 3 percent. Pain or discomfort during recovery was rated mild or less than mild in 94.3 percent of patients and moderate in 5.7 percent; no patients rated their postoperative pain as severe.

Pain that persists for several months after vasectomy is rare. When this occurs, it may be related to persisting inflammation in a sperm granuloma or in the epididymis following an episode of acute epididymitis.<sup>57-60</sup> These situations tend to resolve progressively over time. A neuroma at the site of division of the vas may be persistently tender, though it rarely requires intervention. Distention of the epididymis and vas deferens appears to be common, as noted in post-vasectomy pathology specimens. Rarely, surgical reanastomosis of the vas or resection of the epididymis is performed for those whose pain did not resolve with conservative management (postvasectomy pain syndrome).<sup>47,61</sup>

### Reversal of Vasectomy

A small group of patients, approximately 1 percent to 5 percent, does later request vasectomy reversal.<sup>51</sup> This group is not necessarily dissatisfied with vasectomy, but frequently has encountered an unforeseen change in lifestyle and a renewed desire to restore fertility, usually with a new partner.

Vasovasostomy, surgically rejoining the vasa, succeeds in restoring the conduit for sperm in over 90 percent of cases, however, the rate of pregnancies achieved is in the range of 50 percent to 70 percent. If more than 10 years has passed since the vasectomy, the pregnancy rate drops to about 30 percent.<sup>62,63</sup>

In the author's experience, patients with successful vasovasostomies commonly present later for a second vasectomy.

---

# Adding Vasectomy to Your Practice

For physicians who already offer vasectomy in their office practice, transitioning to NSV requires very little change in procedures. For those who do other minor surgery and are adding vasectomy, it is a good idea to write out the new procedures and share them with your staff. You may need a dedicated surgical tray, or you can add the special instruments to your current minor surgery tray. Give your staff a preoperative checklist that includes instructions on setting up the equipment properly.

In addition, a written procedure for speaking with callers about vasectomy will help the receptionist respond with confidence and welcome the patient who might be particularly anxious about inquiring.

The receptionist can also offer to send written materials to the patient. Customizing materials for your office is ideal. The AAFP and others publish pamphlets that you can use for patient education. See the “Resources” section on page 69 for more information.

Getting the word out that you perform NSV is an important part of adding the procedure to your practice. Let your patients, staff and colleagues (e.g., obstetricians, pediatricians and midwives) know you have added this procedure to your practice. The patients who have the surgery — and their partners — can also spread the news to their friends.

## Training

This training package is intended to provide the physician with a basic understanding of NSV. However, additional training is needed before attempting this procedure. Training is available in procedural workshops sponsored by the AAFP and others.

Every physician beginning NSV is strongly encouraged to arrange with an experienced preceptor for a clinical training session in his or her own practice setting. A personal training session can provide a number of valuable tips specific to the NSV technique, even for trainees who already have had extensive surgical and vasectomy experience and who have

---

excellent surgical skills. Contact a physician in your area who you know to be skilled at NSV, or visit this Web site for a listing of physicians who perform NSV and those who have training experience:  
<http://www.engenderhealth.org/wh/fp/cnsvdr.html>.

## Billing

The CPT procedure code for vasectomy, unilateral or bilateral, is 55250. The ICD-9 code for sterilization is V25.2. Typical charges for vasectomy in the United States range from \$400 to \$850 plus fees for the facility and/or the equipment. As always, benefits and payment levels vary widely from one insurer to another. Government-sponsored programs do not commonly make a reimbursement without a copy of the consent form proving that consent was obtained at least 30 days prior to the procedure.

## Liability and Insurance

A recent review of malpractice liability claims related to vasectomy in the United States revealed that vasectomy does not put physicians at increased risk over other procedures. Of the cases that went to trial, half related to infection or hematoma; the other half related to pregnancy or failure to obtain consent.<sup>64</sup> Full informed consent, including the possibility of pregnancy after vasectomy, should minimize the physician's risk.

Vasectomy is likely to be covered for physicians who are insured for obstetrical care, but may also be included with minor office surgery under most liability insurance plans. Check with your insurer to make sure you're covered.

---

# Resources

Resources for your practice are available from various sources.

## Patient Education Materials

An excellent section on patient education, including answers to common questions on vasectomy, is included in the *Primary Care* article by Davis and Stockton.<sup>50</sup> The article also presents a sample vasectomy encounter form and a patient education and consent form.

A three-page patient information handout is made available for reproduction and physician use in the October 1992 issue of *American Family Physician*, page 1165.

Planned Parenthood Federation of America Inc. provides a patient education pamphlet entitled “All About Vasectomy.” The brochure can be viewed online at <http://www.plannedparenthood.org/bc/allaboutvas.htm>. To order, contact: Marketing Department, Planned Parenthood Federation of America Inc., 810 Seventh Ave., New York, NY 10019. 212-541-7800.

EngenderHealth ([www.engenderhealth.org](http://www.engenderhealth.org)) offers various patient education materials, including a Spanish-language video that explains various family planning methods and a video for men in the United States who are considering vasectomy.

## Physician and Staff Materials

Table 7 lists resources for counseling on sterilization.

EngenderHealth offers curricula for surgeons, support staff and other non-physicians. Visit the EngenderHealth Web site ([www.engenderhealth.org](http://www.engenderhealth.org)) or contact them at 440 Ninth Ave., New York, NY 10001. 212-561-8000.

The following page contains a sample patient consent form.

---

# Vasectomy Consent — Sample Form

State law guarantees that you have both the right and the obligation to make informed decisions about your health care. It is our intent to provide you with complete and accurate information about vasectomy; it is your responsibility to consider all of the options, the risks, and the benefits, and to make the best choice for you.

1. I, the undersigned, request that Dr. \_\_\_\_\_ perform a vasectomy on me. It has been explained to me that this operation is intended to result in permanent sterility, which means that I will no longer be capable of fathering a child.
2. I agree to the administration of local anesthetic (medicine to numb the area of the surgery) or other medications before, during or after the procedure.
3. I understand that vasectomy is not immediately effective and that I must use another method of birth control until a semen test proves that my vasectomy was successful.
4. I recognize that, as with any operation, there are risks, both known and unknown, associated with vasectomy, and that no guarantee has been given to me as to the results of this operation. Possible complications include, but are not limited to, the following:
  - Infection
  - Blood clot (hematoma)
  - Inflammation of the epididymis
  - Painful nodule or scar (sperm granuloma, neuroma)
  - Allergy or adverse reaction to an anesthetic or medication
  - Emotional reactions that could interfere with normal sexual function
  - Failure to achieve or to maintain sterility

I understand and accept that these or other conditions may necessitate further treatment, tests, another operation, procedure and/or hospitalization, at my own expense. I request and authorize Dr. \_\_\_\_\_ and other qualified medical personnel to perform such treatment or procedures as required.

5. I have read and understand the information given to me by Dr. \_\_\_\_\_ and/or his or her staff, including the alternative forms of birth control for both men and women. I understand and will abide by the instructions for care after vasectomy, and I have received a written copy.

I request this operation voluntarily, of my own free choice. I have carefully read or had read to me the above, and I understand and accept the terms and conditions.

Signed: \_\_\_\_\_

Date: \_\_\_\_\_

Spouse: \_\_\_\_\_  
(spouse's signature optional)

Date: \_\_\_\_\_

---



# Learning Package Quiz Review

1. The most commonly used method of contraception for married women ages 15 to 44 in the United States is:
    - A. oral contraceptive
    - B. barrier contraceptive
    - C. sterilization, with vasectomy exceeding tubal sterilization
    - D. sterilization, with tubal sterilization exceeding vasectomy
  2. No-scalpel vasectomy (NSV) is a strictly defined sequence of steps that includes all of the following, EXCEPT:
    - A. vasal block anesthesia
    - B. three-finger fixation
    - C. delivery of a loop of vas
    - D. occluding vas by cautery
  3. TRUE OR FALSE: The advantages of NSV include minimizing discomfort, tissue trauma and bleeding.

True  
False
  4. Which one of the following steps is performed using the vas-fixing forceps?
    - A. grasping 1the vas through the skin during the vasal injection
    - B. puncturing the vas
    - C. delivering the vas
    - D. regrasping the vas after delivery
  5. Performing NSV in a physician's office requires:
    - A. a special procedure room
    - B. special instruments
    - C. an extra heater in the room
    - D. a power tilt table
-

6. TRUE OR FALSE: Optimal lighting for NSV can be provided by a typical gooseneck lamp with a standard bulb.

True

False

7. Which of the following should the physician note during the preoperative examination?

- A. the position and mobility of each vas
- B. any skin infections or masses
- C. minor anomalies in the scrotum unrelated to the vasectomy
- D. all of the above

8. The vas deferens is supplied with visceral nerves along its surface. The vasal block anesthetic works well because:

- A. it blocks these nerves superior to the site of vasectomy
- B. it blocks all sensation in the scrotum
- C. it blocks the cutaneous (somatic) nerves to the anterior scrotum
- D. it diffuses efficiently around the puncture site

9. When positioning to work on the left vas, the right-handed physician:

- A. moves toward the head of the table
- B. faces toward the foot of the table
- C. reaches across the patient's abdomen
- D. A, B and C
- E. moves to the left side of the patient

10. To hold the vas with three-finger fixation, the right-handed physician:

- A. places the right middle finger behind the scrotum
  - B. places only the left middle finger behind the scrotum
  - C. places the thumb behind the scrotum with the index and middle fingers anterior
  - D. pinches the vas through the anterior scrotum between the thumb and index finger
-

11. In performing vasal block anesthesia, the physician should:
- A. inject as he or she advances the needle
  - B. inject the entire bolus at one site after advancing the needle
  - C. move the needle around as he or she injects to surround the vas with anesthetic
  - D. try to place the needle tip into the vas
12. The sensation a patient may expect during paravasal injection is:
- A. stinging or burning
  - B. dull aching that radiates up into the groin
  - C. a sharp snap
  - D. none of the above
13. TRUE OR FALSE: The vas-fixing forceps is designed to be atraumatic; therefore, repeated grasping efforts will not cause swelling or difficulty with vas isolation.
- True  
False
14. When pushing down with the vas-fixing forceps against the pad of the middle finger, it is important to:
- A. push hard to keep the vas from slipping out of the grasp of the forceps
  - B. push hard to identify the vas, which is noncompressible
  - C. push gently to avoid making the patient uncomfortable
  - D. push hard and quickly to minimize the duration of discomfort
15. When grasping the vas in the vas-fixing forceps, the physician should:
- A. lock the forceps before releasing downward pressure
  - B. lock the forceps after releasing downward pressure
  - C. not lock the forceps, in order to avoid pinching the posterior scrotum
  - D. tell the patient he won't feel a thing

16. The puncture is made by:

- A. a sort of twisting, drilling action with one tip of the sharp dissecting forceps
- B. several short stabs with the tip of the sharp dissecting forceps
- C. one smooth pierce with one tip of the sharp dissecting forceps
- D. one smooth pierce with both tips of the sharp dissecting forceps together

17. To deliver the vas, the physician:

- A. scoops the vas out of the sheath by sliding the tip of the sharp dissecting forceps just under the vas and lifting it out
- B. impales the vas with the tip of the sharp dissecting forceps, which acts as a hook to pull the vas from its sheath
- C. pinches the vas with the tips of the sharp dissecting forceps and pulls the vas from its sheath
- D. encircles the bare vas with a second vas-fixing forceps and gently lifts it from its sheath

18. To regrasp the loop with the vas-fixing forceps, the physician should:

- A. pinch the vas
- B. encircle the vas
- C. pinch only the fascia
- D. protect the vasal artery by encircling it with the vas-fixing forceps

19. TRUE OR FALSE: There are several acceptable methods of occluding the vas deferens that may be used with the NSV technique.

True  
False

20. TRUE OR FALSE: Fascial interposition is an essential step in NSV.

True  
False

---

21. After occluding the second vas, the physician should do all of the following, EXCEPT:

- A. allow the vas to slip back into the scrotum
- B. place a stitch in the skin layer
- C. apply pressure to the puncture site for 5 to 10 minutes
- D. tuck a gauze pad into the patient's clean, snug briefs

22. TRUE OR FALSE: Giving postoperative instructions verbally at the end of the procedure is the best way to gain patient compliance.

- True
- False

23. Medications for pain after vasectomy for most patients include:

- A. oxycodone
- B. acetaminophen
- C. ibuprofen or naproxen sodium
- D. B and C

24. TRUE OR FALSE: Because of the known failure rate of vasectomy, it is essential that the physician attempt to contact any patient who has not completed postoperative testing.

- True
- False

25. TRUE OR FALSE: A follow-up phone call to the patient on the day after his vasectomy is a good tool for providing reassurance and reinforcing postoperative instructions.

- True
  - False
-

# References

1. Magnani RJ, Haws JM, Morgan GT, Gargiullo PM, Pollack AE, Koonin LM. Vasectomy in the United States, 1991 and 1995. *AM J Public Health* 1999; 89(1):92-4.
  2. Vasectomy: new opportunities. *Pop Rep* 1992;D(5):1-23.
  3. Li SQ, Goldstein M, Zhu J, Huber D. The no-scalpel vasectomy. *J Urol* 1991;145:341-4.
  4. Haws JM, Morgan GT, Pollack AE, Koonin LM, Magnani RJ, Gargiullo PM. Clinical aspects of vasectomies performed in the United States in 1995. *Urology* 1998;52(4):685-91.
  5. Smucker DR, Mayhew HE, Nordlund DJ, Hahn WK Jr, Palmer KE. Postvasectomy semen analysis: why patients don't follow-up. *J Am Board Fam Pract* 1991;4:5-9.
  6. Dervin JV, Barnett RC, Stone DL. Patient noncompliance with postvasectomy semen examination protocol. *J Fam Pract* 1982;14:487-90.
  7. Edwards IS. Earlier testing after vasectomy, based on the absence of motile sperm. *Fertil Steril* 1993;59:431-6.
  8. Philp T, Guillebaud J, Budd D. Complications of vasectomy: review of 16,000 patients. *Br J Urol* 1984;56:745-8.
  9. Philp T, Guillebaud J, Budd D. Late failure of vasectomy after two documented analyses showing azoospermic semen. *Br Med J* 1984;289:77-9.
  10. Alderman PM. The lurking sperm. A review of failures in 8879 vasectomies performed by one physician. *JAMA* 1988;259:3142-4.
  11. Babayan RK, Krane RJ. Vasectomy: what are community standards? *Urology* 1986;27(4):328-30.
  12. Bengner JR, Swami SK. Persistent spermatozoa after vasectomy: a survey of British urologists. *Br J Urol* 1995;76:376-9.
  13. Davis JE. Male sterilization. *Curr Opin Obstet Gynecol* 1992;4:522-6.
  14. Freund M, Davis JE. Disappearance rate of spermatozoa from the ejaculate following vasectomy. *Fertil Steril* 1969;20:163-70.
  15. Alexander NJ, Clarkson TB. Vasectomy increases the severity of diet-induced atherosclerosis in *Macaca fascicularis*. *Science* 1978;201:538-41.
  16. Clarkson TB, Alexander NJ, Morgan TM. Atherosclerosis of cynomolgus monkeys hyper- and hyporesponsive to dietary cholesterol. Lack of effect of vasectomy. *Arteriosclerosis* 1988;8:488-98.
-

17. Rosenberg L, Palmer JL, Zauber AG, Warshauer ME, Stolley PD, Shapiro S. Vasectomy and the risk of prostate cancer. *Am J Epidemiol* 1990;132:1051-5; discussion 1062-5.
  18. Mettlin C, Natarajan N, Huben R. Vasectomy and prostate cancer risk. *Am J Epidemiol* 1990;132:1056-61; discussion 1062-5.
  19. Giovannucci E, Tosteson TD, Speizer FE, Vessey MP, Colditz GA. A long-term study of mortality in men who have undergone vasectomy. *N Engl J Med* 1992;326:1392-8.
  20. Sidney S. Vasectomy and the risk of prostatic cancer and benign prostatic hypertrophy. *J Urol* 1987;138:795-7.
  21. Sidney S, Quesenberry CP Jr, Sadler MC, Guess HA, Lydick EG, Cattolica EV. Vasectomy and the risk of prostate cancer in a cohort of multiphasic health-checkup examinees: second report. *Cancer Causes Control* 1991;2(2):113-6.
  22. Giovannucci E, Tosteson TD, Speizer FE, Ascherio A, Vessey MP, Colditz GA. A retrospective cohort study of vasectomy and prostate cancer in US men. *JAMA* 1993;269:878-82.
  23. National Institutes of Health, National Institute of Child Health and Human Development, National Cancer Institute, National Institute of Diabetes and Digestive and Kidney Diseases. Final Statement, Vasectomy and Prostate Cancer Conference. Bethesda, MD: National Institutes of Health; March 2, 1993.
  24. John EM, Whittemore AS, Wu AH, Kolonel LN, Hislop TG, Howe GR, et al. Vasectomy and prostate cancer: Results from a multiethnic case-control study. *J Natl Cancer Inst* 1995 3;87:662-9.
  25. Rosenberg L, Palmer JR, Zauber AG, Warshauer ME, Strom BL, Harlap S, et al. The relation of vasectomy to the risk of cancer. *Am J Epidemiol* 1994 1; 140:431-8.
  26. Zhu K, Stanford JL, Daling JR, McKnight B, Stergachis A, Brawer MK, et al. Vasectomy and prostate cancer: a case-control study in a health maintenance organization. *Am J Epidemiol* 1996;144:717-22.
  27. Peterson HB, Howards SS. Vasectomy and prostate cancer: the evidence to date. *Fertil Steril* 1998;70(2):201-3.
  28. Lesko SM, Louik C, Vezina R, Rosenberg L, Shapiro S. Vasectomy and prostate cancer. *J Urol* 1999;161:1848-52; discussion 1852-3.
  29. Bernal-Delgado E, Latour-Perez J, Pradas-Arnal F, Gomez-Lopez LI. The association between vasectomy and prostate cancer: a systematic review of the literature. *Fertil Steril* 1998;70(2):191-200.
-

30. Jarow JP, Goluboff ET, Chang TS, Marshall FF. Relationship between antisperm antibodies and testicular histologic changes in humans after vasectomy. *Urology* 1994;43(4):521-4.
  31. Joshi UM. Endocrine and accessory sex organ function after vasectomy and vasovasostomy. *Arch Androl* 1981;7(2):187-91.
  32. Linnet L. Vasectomy and health revisited. *Int J Androl* 1993;16(3):169-73.
  33. Massey FJ, Bernstein GS, O'Fallon WM, Schuman LM, Coulson AH, Crozier R, et al. Vasectomy and health. Results from a large cohort study. *JAMA* 1984;252:1023-9.
  34. Rosenberg L, Schwingl PJ, Kaufman DW, Helmrich SP, Palmer JR, Shapiro S. The risk of myocardial infarction 10 or more years after vasectomy in men under 55 years of age. *Am J Epidemiol* 1986;123:1049-56.
  35. Goldacre MJ, Holford TR, Vessey MP. Cardiovascular disease and vasectomy. Findings from two epidemiologic studies. *N Engl J Med* 1983;308:805-8.
  36. Giovannucci E, Ascherio A, Rimm EB, Colditz GA, Stampfer MJ, Willett WC. A prospective cohort study of vasectomy and prostate cancer in US men. *JAMA* 1993;269:873-7.
  37. Pollack AE, Carignan C, Pati S. What's new with male sterilization: an update. *Contemp Ob Gyn* 1998;43:41-67.
  38. Moss WM. Vasectomy failure after use of an open-ended technique. *Fertil Steril* 1985;43:667-8.
  39. Errey BB, Edwards IS. Open-ended vasectomy: an assessment. *Fertil Steril* 1986;45:843-6.
  40. Shapiro EI, Silber SJ. Open-ended vasectomy, sperm granuloma, and postvasectomy orchalgia. *Fertil Steril* 1979;32:546-50.
  41. Goldstein M. Vasectomy failure using an open-ended technique. *Fertil Steril* 1983;40:699-700.
  42. Denniston GC. Vasectomy by electrocautery: outcomes in a series of 2,500 patients. *J Fam Pract* 1985;21(1):35-40.
  43. Schmidt SS. Vasectomy. *JAMA* 1988;259:3176.
  44. Raspa RF. Complications of vasectomy. *Am Fam Phys* 1993;48:1264-8.
  45. Schmidt SS. Vasectomy by section, luminal fulguration and fascial interposition: results from 6248 cases. *Br J Urol* 1995;76:373-4; discussion 375.
-



46. McMahon AJ, Buckley J, Taylor A, Lloyd SN, Deane RF, Kirk D. Chronic testicular pain following vasectomy. *Br J Urol* 1992;69(2):188-91.
  47. Hayden LJ. Chronic testicular pain. *Aust Fam Phys* 1993;22:1357-9, 1362, 1365.
  48. Schmidt SS. Clinical aspects of vasectomy. *Urology* 1999;53:862.
  49. Ehn BE, Liljestrand J. Experiences of legal sterilization in Scandinavia. *Contraception* 1993;48:157-67.
  50. Davis LE, Stockton MD. Office Procedures. No-scalpel vasectomy. *Prim Care* 1997;24:433-61.
  51. Belker A. Vasectomy and its reversal. *Prim Care* 1985;12:703-17.
  52. Hatcher RA, Trussell J, Stewart F, Cates W Jr, Stewart GK, Guest F, et al. *Contraceptive technology*. 17th ed. New York: Ardent Media Inc.; 1990.
  53. Pati S, Pollack AE, Carignan C, Muirhead G. What's new in female sterilization. *Patient Care* 1999;33(5):118-42.
  54. Alderman PM, Morrison GE. Standard incision or no-scalpel vasectomy? *J Fam Pract* 1999;48:719-21.
  55. Pfenninger JL. Complications of vasectomy. *Am Fam Phys* 1984;30:111-5.
  56. Viddeleer AC, Lycklama a Nijeholt G. Lethal Fournier's gangrene following vasectomy. *J Urol* 1992;147:1613-4.
  57. McCormack M, Lapointe S. Physiologic consequences and complications of vasectomy. *CMAJ* 1988;138(3):223-5.
  58. Schmidt SS, Minckler TM. The vas after vasectomy: comparison of cauterization methods. *Urology* 1992;40:468-70.
  59. Chen TF, Ball RY. Epididymectomy for post-vasectomy pain. *Br J Urol* 1991;68(4):407-13.
  60. Schned AR, Selikowitz SM. Epididymitis nodosa. *Arch Pathol Lab Med* 1986;110:61-4.
  61. McDonald SW. Vasectomy review: sequelae in the human epididymis and ductus deferens. *Clin Anat* 1996;9:337-42.
  62. Goldstein M. Reversing vasectomy. *Med Aspects Hum Sex* 1990:57.
  63. Fox M. Vasectomy reversal by microsurgery. *Practitioner* 1993;237:473-6.
  64. Haws JM, Feigin J. Vasectomy counseling. *Am Fam Phys* 95;52:1395-99.
-